

Turbo Cancer: Tenth Cancer Case After COVID-19 mRNA Vaccination (Massive Skin Cancer)

Dr. Seneff and Dr. McCullough Publish Tenth Cancer Cases After COVID-19 mRNA Vaccination

By [Dr. William Makis](#)

Theme: [Science and Medicine](#)

Global Research, September 24, 2023

[COVID Intel](#) 22 September 2023

All Global Research articles can be read in 51 languages by activating the Translate Website button below the author's name.

To receive Global Research's Daily Newsletter (selected articles), [click here](#).

Click the share button above to email/forward this article to your friends and colleagues. Follow us on [Instagram](#) and [Twitter](#) and subscribe to our [Telegram Channel](#). Feel free to repost and share widely Global Research articles.

Did you know there are now 10 cases of cancer after COVID-19 mRNA vaccination in the literature? Here they are:

"Turbo Cancer" post mRNA vaccine papers reviewed:

- [Sep. 2023 - Seneff, McCullough](#) - 56M skin cancer after 1st Pfizer mRNA
- [May 2023 - Eens et al](#) - Mouse develops lymphoma after 2nd Pfizer mRNA
- [April 2023 - Tachita et al](#) - 73M develops lymphoma after 2nd Pfizer mRNA
- [Jan 2023 - Cavanna et al](#) - 66M develops lymphoma after 3rd Pfizer mRNA
- [Sep 2022 - Revenga-Porcel et al](#) - 76M lymphoma after 3rd Moderna mRNA
- [Aug 2022 - Sekizawa et al](#) - 80F lymphoma after 2nd Pfizer mRNA
- [June 2022 - Zamfir et al](#) - 58F 2nd Pfizer, 53M 2nd Pfizer both lymphoma
- [Apr 2022 - Mitsui et al](#) - 67M 2nd Pfizer, 80F 2nd Pfizer both lymphoma
- [Nov. 2021 - Goldman et al](#) - 66M lymphoma progression after 3rd Pfizer mRNA

[New paper](#) by Dr. Stefanie Seneff and Dr. Peter McCullough

- 56 year old man had 1st Pfizer mRNA dose
- 4 days later he started having right TMJ pain which worsened over time
- 2 months after Pfizer he was diagnosed with right-sided trigeminal neuralgia and cranial nerve VII palsy
- 4 months after Pfizer he started losing weight, lost 12 kg
- 8 months after Pfizer he had deafness in right ear, couldn't open right eye, couldn't open right side of his mouth, total paralysis of right face and a large mass blocking the external auditory canal - diagnosed as basaloid cell carcinoma

- 15 months after Pfizer (1st picture above – extreme cavitation in the preauricular region, extreme necrosis of the skin and extensive infiltrations of vasculature)

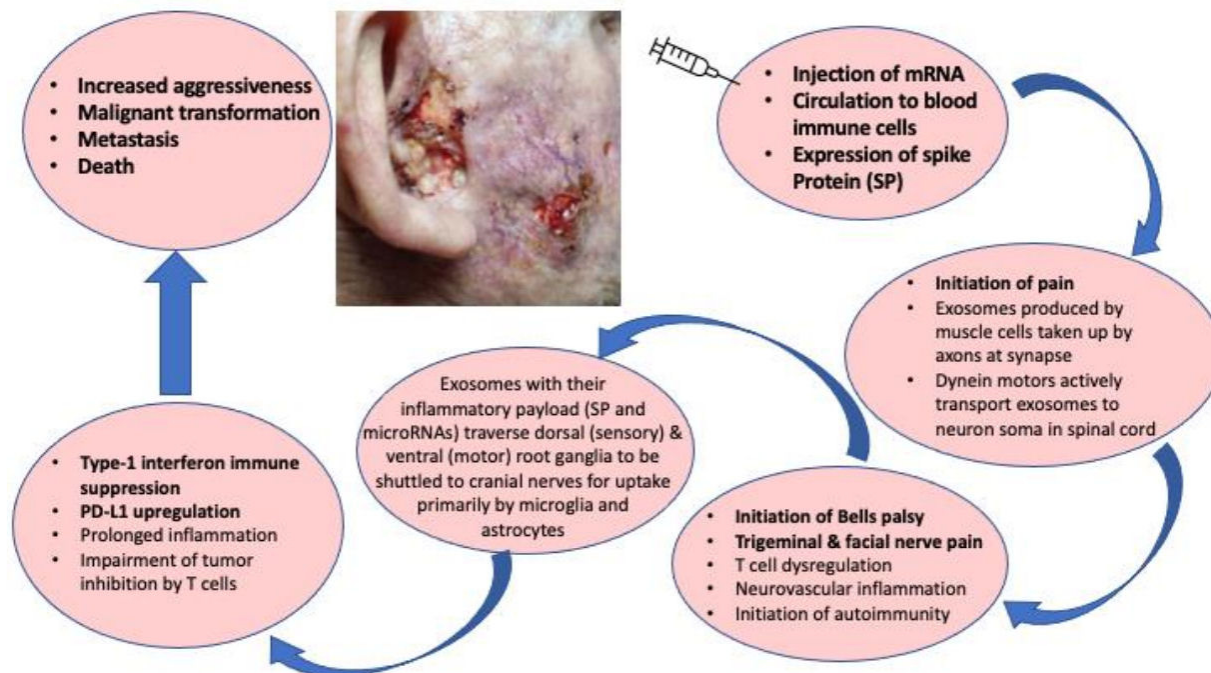


Figure 1: Graphical abstract

[May 2023 – Eens et al](#) – Mouse develops lymphoma after 2nd Pfizer mRNA

- I don't count this as part of the 10 cases but I include it here for completeness
- They injected 14 mice with two Pfizer COVID-19 mRNA vaccines.
- Two days after the 2nd dose and 16 days after 1st dose, one of the mice died suddenly without any warning.
- necropsy showed extensive, systemic infiltration of liver, kidneys, spleen, lungs, and intestines" by a lymphoma

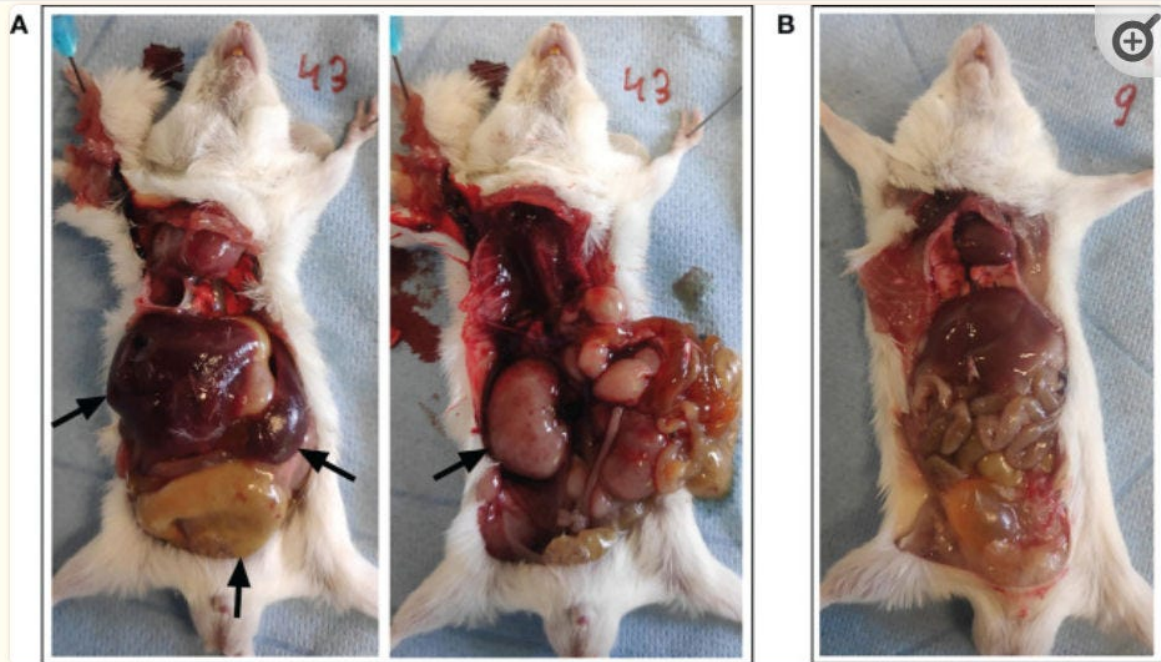
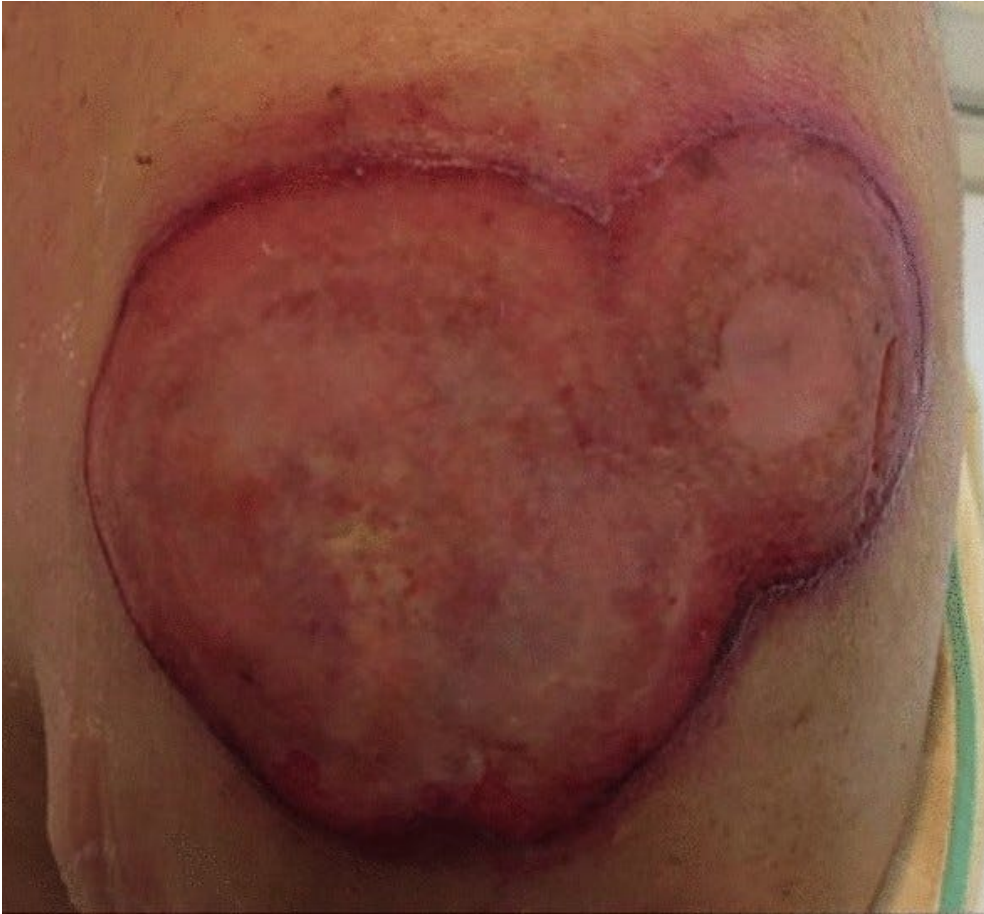

Figure 2

Necropsy examination of organs following spontaneous death. **(A)** A disproportional enlargement of several of the animal's major organs was observed at necropsy, including the liver, kidneys, spleen, and intestines (*black arrows*). **(B)** Animal with normal phenotype for reference.

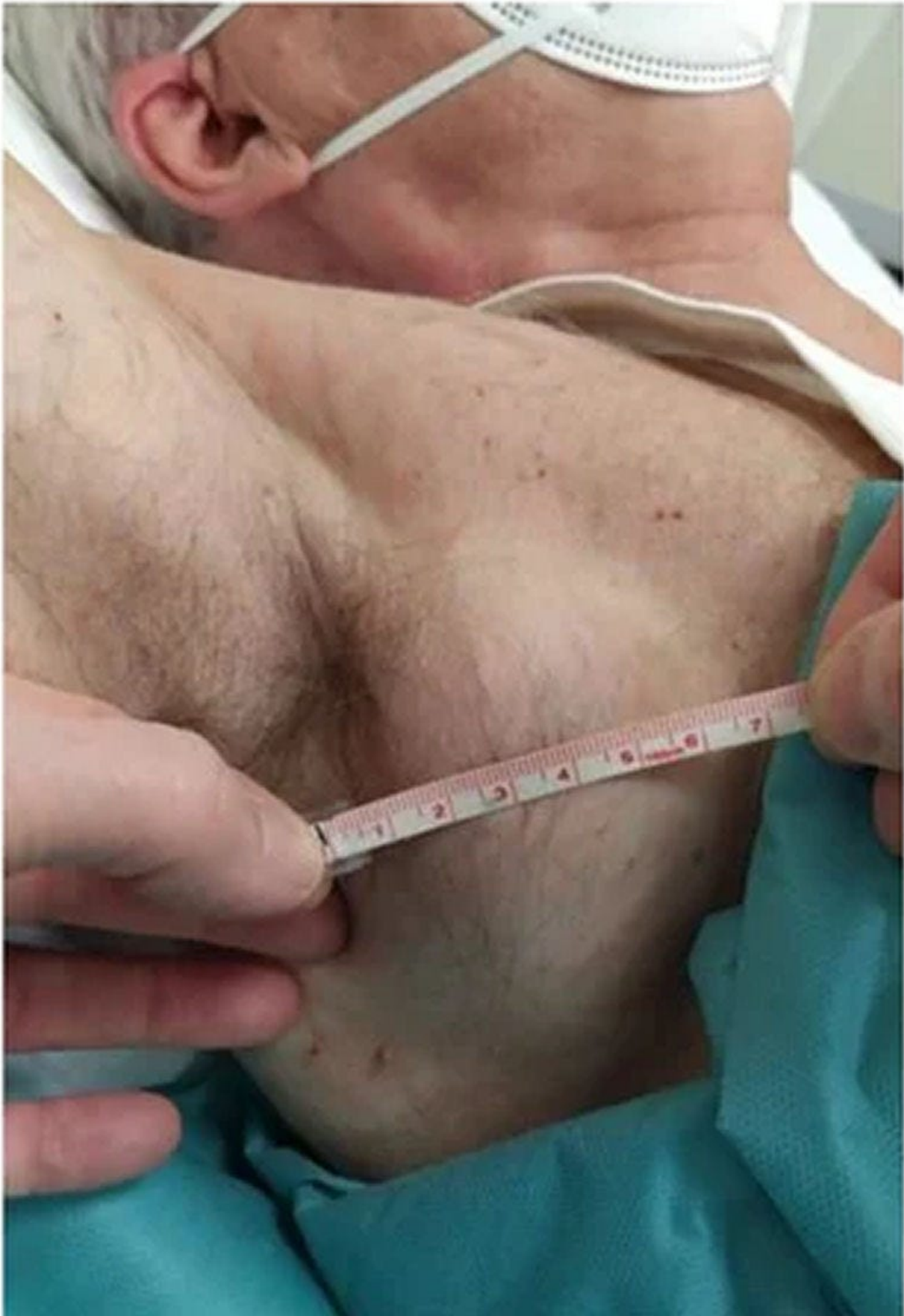[April 2023 - Tachita et al](#) - 73M develops lymphoma after 2nd Pfizer mRNA

- 73 year old Japanese man presented with a lump in left arm where he had his 2nd Pfizer mRNA vaccine three months prior.
- he then developed 6cm and 3cm ulcerated lesions in the left arm
- he was diagnosed with Extranodal NK/T-cell lymphoma, nasal type (ENKL), a natural killer (NK) cell malignancy



[Jan 2023 – Cavanna et al](#) – 66M develops Stage 2 NHL lymphoma post 3rd Pfizer mRNA

- 66 year old Italian man developed swollen right axillary lymph nodes 10 days after 3rd Pfizer mRNA (booster) dose.
- 3 months later he presented to the clinic with a 7cm mass in right axilla and 2cm lesion in right supraclavicular region
- He was diagnosed with a Stage 2 NHL Lymphoma, Ki-67 90%



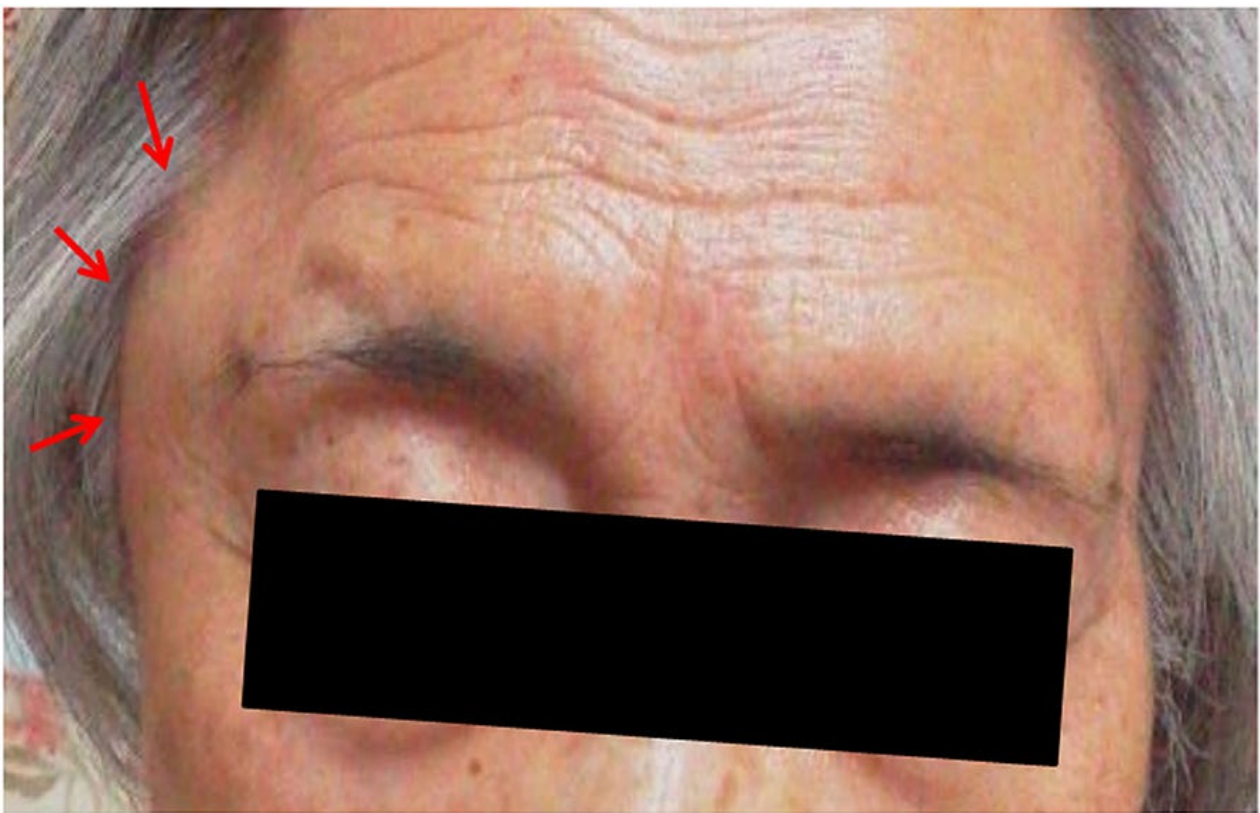[Sep 2022 - Revenga-Porcel et al](#) - 76M develops lymphoma after 3rd Moderna mRNA

- this paper is behind a paywall
- 76 year old man developed 7cm mass in right arm 10 days after 3rd Moderna mRNA

- diagnosed with PC-ALCL (very aggressive lymphoma - Primary cutaneous anaplastic large cell lymphoma (PCALCL) is a subtype of cutaneous T-cell lymphoma (CTCL), and is a non-Hodgkin lymphoma that arises in the skin

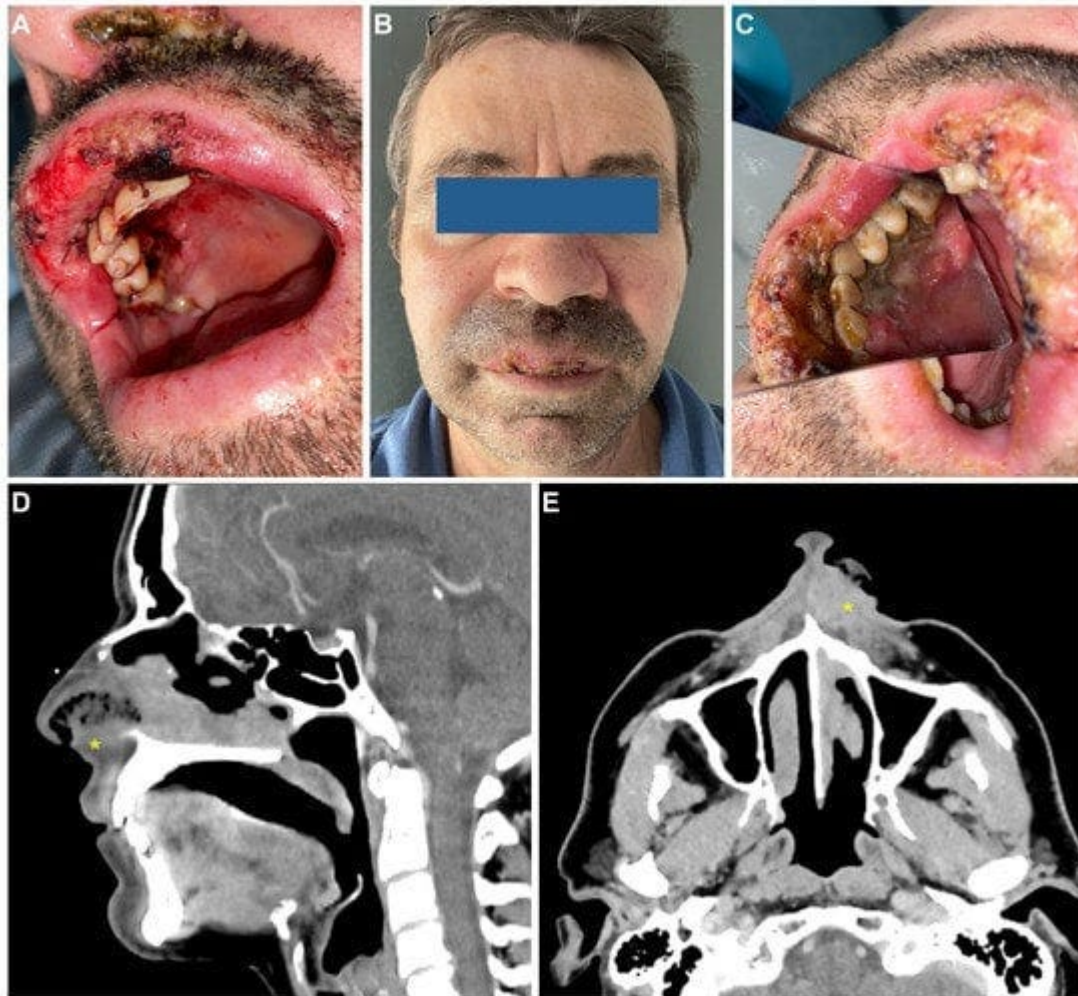[Aug 2022 - Sekizawa et al](#) - 80F lymphoma after 2nd Pfizer mRNA

- 80 year old Japanese woman developed a right temporal mass the day after 1st Pfizer mRNA
- she was given tylenol and took a 2nd Pfizer mRNA 3 weeks later
- she then presented again 3 weeks after 2nd Pfizer dose and mass was 3cm
- at around 13 weeks the mass grew to 7cm
- right temporal mass was diagnosed as a subtype of MZL (extranodal marginal zone lymphoma of the mucosa-associated lymphoid tissue or nodal marginal zone lymphoma) stage IIE



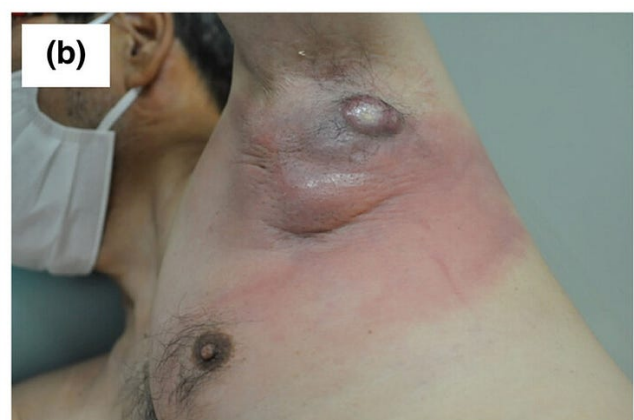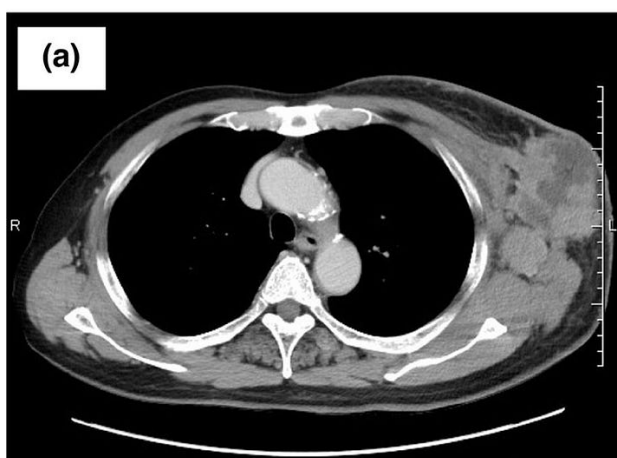
[June 2022 - Zamfir et al](#) - 58F and 53M develop lymphoma post 2nd Pfizer mRNA

- 58 year old Romanian woman developed 4cm left neck mass that appeared one week after 2nd Pfizer dose
- the 4cm mass and two lymph nodes were diagnosed DLBCL lymphoma, Ki-67 80%
- 53 year old Romanian man had 2 Pfizer mRNA vaccines
- On the third day after the first dose, he noticed a painless ulcer on the mucosal surface of the upper lip. He initiated self-treatment with topical vitamin A. The lesion extended and new lesions developed
- These lesions had a progressive character and during the following months were complicated with repetitive episodes of heavy oral bleeding, requiring blood transfusions. Biopsy confirmed the diagnosis of T/NK-cell lymphoma



[Apr 2022 - Mitsui et al](#) - 67M and 80F develop lymphoma post Pfizer mRNA

- 67 year old Japanese man presented with a 6 cm subcutaneous mass in the left axilla 2 weeks after 2nd Pfizer mRNA.
- Tenderness and a palpable lymph node in the left axilla were noted 1 day after 1st Pfizer mRNA
- He was diagnosed with DLBCL Lymphoma with Ki-67 > 80%

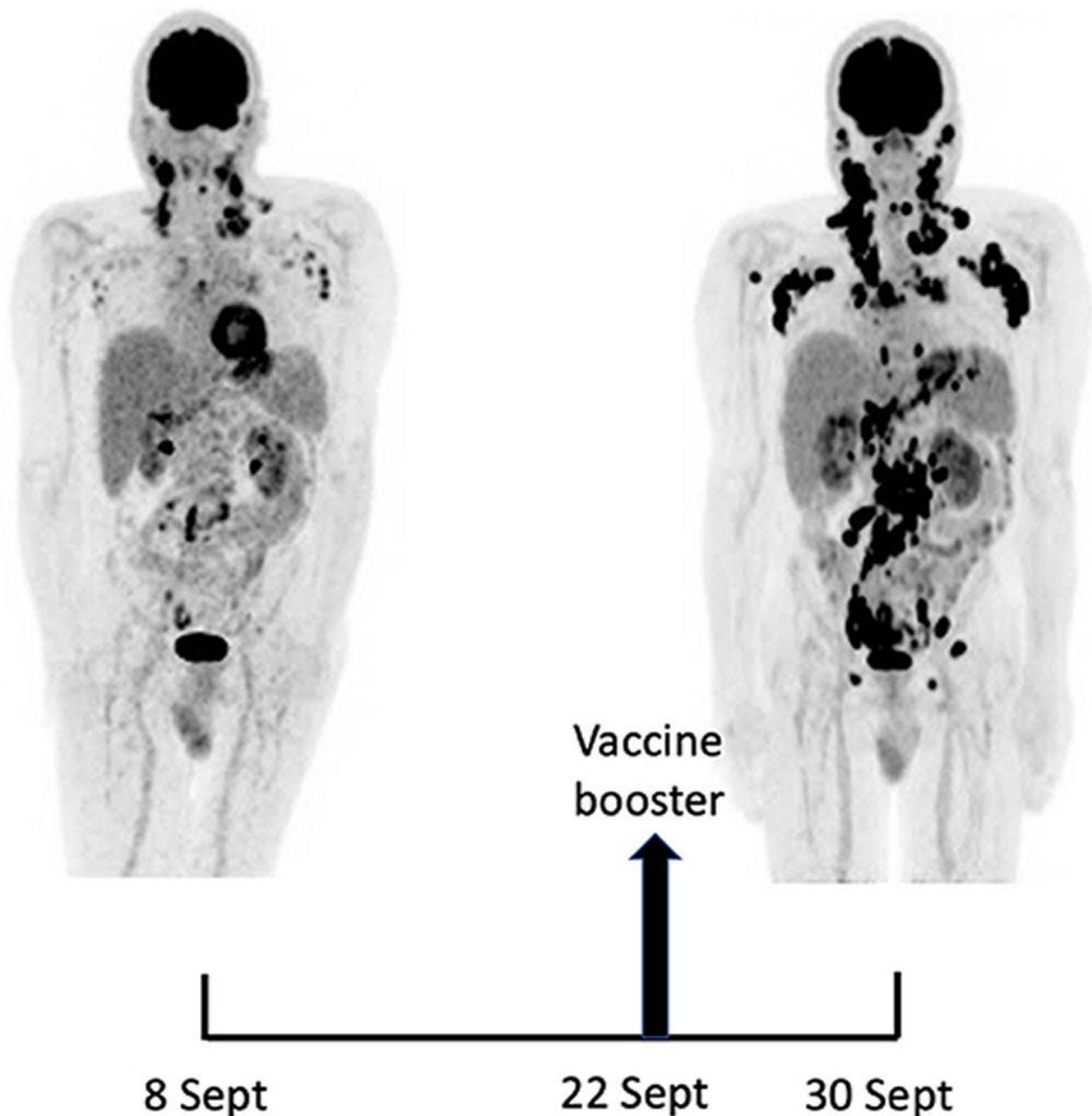


- 80-year-old Japanese woman presented with a 4cm enlarging nodule in her left axilla 1 day after 2nd Pfizer mRNA
- The nodule appeared 2 days after the first vaccination.

- Two months after the first consultation, the nodule gradually enlarged, and computed tomography revealed a 6.0-cm mass in the left axilla and another 2.8-cm mass in the left mesentery
- she was diagnosed with germinal centre B-cell DLBCL lymphoma, Ki-67 > 90%
- patient complained of diplopia and left eyelid ptosis 8 days after the biopsy. Magnetic resonance imaging detected a small tumour, a suspicious DLBCL lesion, in the left cavernous sinus, which was treated with radiation therapy

[Nov. 2021 - Goldman et al](#) - 66M lymphoma progression after Pfizer booster

- 66 year old man had 2 Pfizer mRNA doses and 5 months after 2nd dose presented with axillary lesions
- He was diagnosed with Angioimmunoblastic T Cell Lymphoma
- He then had a Pfizer mRNA booster shot and a few days later presented with neck swelling.
- A repeat PET/CT scan done 8 days after Pfizer mRNA 3rd dose (booster) showed extensive progression of lymphoma.



My Take...

The goal of this article was to bring together all the cases of COVID-19 mRNA vaccine induced Turbo Cancer in the literature.

There are now 10 published cases. And this is only the beginning.

When the dam finally breaks, there will be 100s, then 1000s of these cases.

Right now it's mostly lymphomas.

But I am seeing Turbo Cancers with lymphomas, brain cancers, breast, colon and lung cancers as the top 5, with signals in leukemias and hepatobiliary cancers.

I will not cover the possible mechanisms here but I will point out that Ki-67 is extremely important.

[Ki-67 is a proliferation index](#) determined with special staining during pathology, and a Ki-67 of 90% means 90 out of 100 cells are dividing.

It indicates how rapidly growing a tumor is. 90% is extreme.

“Tumors with a high Ki-67 index have a larger number of proliferating cells and are therefore likely to grow more quickly”

It also predicts long term survival in a number of cancers.


A high Ki-67 usually carries a very poor prognosis.

*

Note to readers: Please click the share button above. Follow us on Instagram and Twitter and subscribe to our Telegram Channel. Feel free to repost and share widely Global Research articles.

Dr. William Makis is a Canadian physician with expertise in Radiology, Oncology and Immunology. Governor General's Medal, University of Toronto Scholar. Author of 100+ peer-reviewed medical publications.

Featured image is from Children's Health Defense



The Worldwide Corona Crisis, Global Coup d'Etat Against Humanity

by Michel Chossudovsky

Michel Chossudovsky reviews in detail how this insidious project “destroys people’s lives”. He provides a comprehensive analysis of everything you need to know about the “pandemic” — from the medical dimensions to the economic and social repercussions, political underpinnings, and mental and psychological impacts.

“My objective as an author is to inform people worldwide and refute the official narrative which has been used as a justification to destabilize the economic and social fabric of entire countries, followed by the imposition of the “deadly” COVID-19 “vaccine”. This crisis affects humanity in its entirety: almost 8 billion people. We stand in solidarity with our fellow human beings and our children worldwide. Truth is a powerful instrument.”

Reviews

This is an in-depth resource of great interest if it is the wider perspective you are motivated to understand a little better, the author is very knowledgeable about geopolitics and this comes out in the way Covid is contextualized. —Dr. Mike Yeadon

In this war against humanity in which we find ourselves, in this singular, irregular and massive assault against liberty and the goodness of people, Chossudovsky’s book is a rock upon which to sustain our fight. –Dr. Emanuel Garcia

In fifteen concise science-based chapters, Michel traces the false covid pandemic, explaining how a PCR test, producing up to 97% proven false positives, combined with a relentless 24/7 fear campaign, was able to create a worldwide panic-laden “plandemic”; that this plandemic would never have been possible without the infamous DNA-modifying Polymerase Chain Reaction test – which to this day is being pushed on a majority of innocent people who have no clue. His conclusions are evidenced by renown scientists. —Peter Koenig

Professor Chossudovsky exposes the truth that “there is no causal relationship between the virus and economic variables.” In other words, it was not COVID-19 but, rather, the deliberate implementation of the illogical, scientifically baseless lockdowns that caused the shutdown of the global economy. –David Skripac

A reading of Chossudovsky’s book provides a comprehensive lesson in how there is a global coup d’état under way called “The Great Reset” that if not resisted and defeated by freedom

loving people everywhere will result in a dystopian future not yet imagined. Pass on this free gift from Professor Chossudovsky before it's too late. You will not find so much valuable information and analysis in one place. -Edward Curtin

ISBN: 978-0-9879389-3-0, Year: 2022, PDF Ebook, Pages: 164, 15 Chapters

Price: ~~\$11.50~~ FREE COPY! [Click here \(docsend\) and download.](#)

We encourage you to support the eBook project by making a donation through Global Research's [DonorBox "Worldwide Corona Crisis" Campaign Page](#).

The original source of this article is [COVID Intel](#)
Copyright © [Dr. William Makis](#), [COVID Intel](#), 2023

[Comment on Global Research Articles on our Facebook page](#)

[Become a Member of Global Research](#)

Articles by: [Dr. William Makis](#)

Disclaimer: The contents of this article are of sole responsibility of the author(s). The Centre for Research on Globalization will not be responsible for any inaccurate or incorrect statement in this article. The Centre of Research on Globalization grants permission to cross-post Global Research articles on community internet sites as long the source and copyright are acknowledged together with a hyperlink to the original Global Research article. For publication of Global Research articles in print or other forms including commercial internet sites, contact: publications@globalresearch.ca

www.globalresearch.ca contains copyrighted material the use of which has not always been specifically authorized by the copyright owner. We are making such material available to our readers under the provisions of "fair use" in an effort to advance a better understanding of political, economic and social issues. The material on this site is distributed without profit to those who have expressed a prior interest in receiving it for research and educational purposes. If you wish to use copyrighted material for purposes other than "fair use" you must request permission from the copyright owner.

For media inquiries: publications@globalresearch.ca