

# Pericarditis: The Other, Less Talked About COVID-19 mRNA Vaccine-Induced Heart Inflammation that Disables or Kills You

13 Cases Explored

By [Dr. William Makis](#)

Global Research, June 06, 2023

[COVID Intel](#) 5 June 2023

Theme: [Science and Medicine](#)

All Global Research articles can be read in 51 languages by activating the Translate Website button below the author's name.

To receive Global Research's Daily Newsletter (selected articles), [click here](#).

Click the share button above to email/forward this article to your friends and colleagues. Follow us on [Instagram](#) and [Twitter](#) and subscribe to our [Telegram Channel](#). Feel free to repost and share widely Global Research articles.

\*\*\*

*May 21, 2021 - Hartford, CT - 17 year old Gregory Hatton developed pericarditis three days after his second dose of Pfizer COVID-19 mRNA vaccine ([click here](#))*

"Gregory is now out of work, on medication and hooked up to a heart monitor". His mother says: "He basically has a heart conditions now".



**COVID VACCINE**

## Mom of Conn. Teen Speaks After Son Suffers Heart Condition Days After COVID-19 Vaccine

"I wouldn't want any other parent to go through what we've been through," said Rachel Hatton, after her 17-year-old son was diagnosed with a heart condition days after receiving the COVID vaccine.

By Jennifer Joas • Published May 25, 2021 • Updated on May 25, 2021 at 1:00 pm

**Up Next**

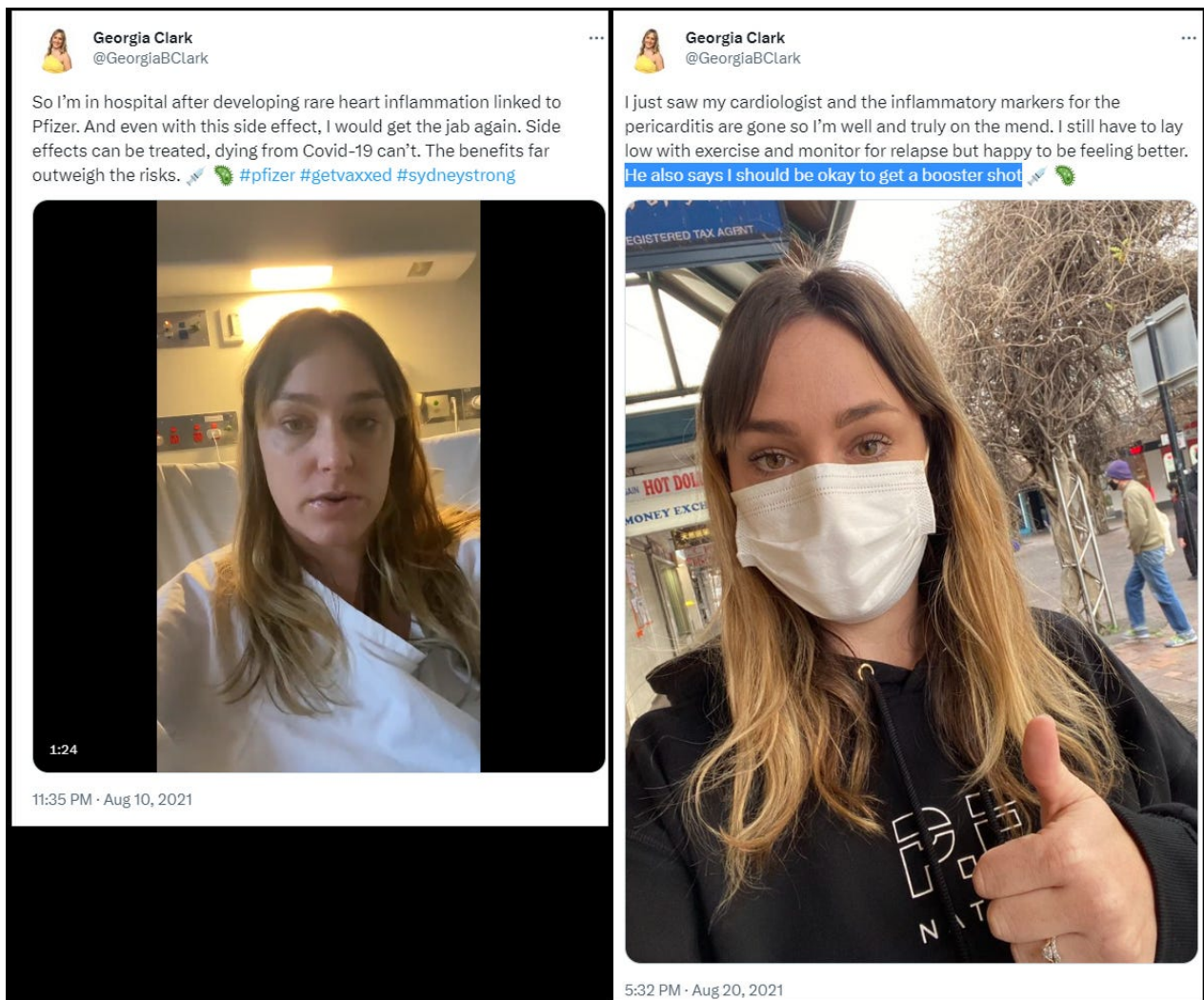A 17-year-old young man from Naugatuck on medication and he has been monitored after doctors diagnosed he had

At least 18 teens and young adults in Connecticut have shown symptoms of heart problems after receiving the COVID-19 vaccine, acting health commissioner Dr. Deirdre Gifford said Monday.

**Trending Stories**

- WASHINGTON DC**  
No Survivors Found After Plane Crashes in Virginia; Fighter Jet Response Causes Sonic Boom Across DC Area
- WATERBURY**  
Homicide Investigation Underway in Waterbury
- MIDDLETOWN**  
Motorcyclist Seriously Hurt in Middletown Crash
- STORRS**  
Search for Missing Storrs Hiker in Japan Ends

Aug. 2021 – Australia – 24-year old journalist Georgia Clark had pericarditis after her second COVID-19 mRNA vaccine. After being hospitalized she said: “I would get the jab again”. Doctors OK’d her to get booster ([click here](#))



Aug. 2021 – 38-year old volleyball champion Francesca Marcon developed pericarditis after second Pfizer mRNA dose that took her out of competition ([click here](#))



## Francesca Marcon: 38-year-old Italian volleyball player develops pericarditis after second Pfizer mRNA injection, wonders "who pays the price"

August 26, 2021 admin

TheCOVIDBlog.com

August 26, 2021



25

*"Perhaps this speech of mine may be a bit blasphemous, but I ask myself: is there no form of compensation for those who suffer health damage after getting the vaccine? I state that I am not anti-vax but I have never been convinced of making this vaccine and I have had confirmation. I don't know if you are interested but I have had and still have post vaccine pericarditis. Who pays the price for all this? Have a good evening."*

Nov. 2021 - 29-year old professional mountain bike racer Kyle Warner developed pericarditis & other injuries after second Pfizer mRNA jab. ([click here](#))



## Professional Mountain Bike Racer Describes Life-Altering Vaccine Injuries After Second Pfizer COVID Shot

Kyle Warner, a 29-year-old professional mountain bike racer, developed [pericarditis](#), POTS and reactive arthritis following his second dose of Pfizer's COVID shot.

### Story at-a-glance:

- Kyle Warner, a 29-year-old professional mountain bike racer, developed [pericarditis](#), POTS and reactive arthritis following his second dose of Pfizer's COVID-19 shot.
- About two weeks after the shot, Warner experienced extremely elevated heart rates; an ER doctor refused to believe it was an adverse reaction to the jab and instead blamed it on a "psychotic episode."
- After visiting another hospital due to more heart trouble, Warner was referred to a cardiologist who diagnosed him with pericarditis, an inflammation of the outer lining of the heart.
- For four months now, Warner has been so ill that he hasn't been able to work or ride a bike — even mental exertion can cause him to relapse physically.
- At the Real, Not Rare rally held in Washington, D.C., Warner spoke before politicians to make a difference in the support level for vaccine-injured people — which is nonexistent in the U.S. — and voice opposition to vaccine mandates. "I believe where there is risk, there needs to be choice," he said

Kyle Warner is 29 years old and was at the peak of his career as a professional mountain bike racer when, in June, he got his second dose of [Pfizer's COVID-19](#) shot. He suffered a reaction so severe that, as of October, he was still spending days in bed, easily overwhelmed by too

Dec. 2021 – 33-year old C.M.Boling was injured after her third Pfizer jab, with pericarditis which left her on bed rest for seven months & in wheelchair



**#CanWeTalkAboutIt**

**C. M. Boling** @dogvoyages · Jul 26, 2022  
 #vaccineinjury success! After SEVEN MONTHS of bed rest and severe disability, I'm finally feeling well enough to take our van, Sophie, out for her maiden voyage. I'm not fully recovered yet but have improved so much ❤️

**C. M. Boling** @dogvoyages · Jul 23, 2022  
 THIS.  
 I haven't been able to stand up for more than a minute in seven months and still don't have a diagnosis.

**C. M. Boling** @dogvoyages · Jul 24, 2022  
 221 days of needing to use a shower chair to shower, a wheelchair to get around the house, and a mobility scooter in public. I'm 33 years old and my symptoms started the day after my third dose of the "safe and effective" Pfizer vaccine.

#VaccineSideEffects  
 #vaccineinjuries



**C. M. Boling** @dogvoyages · Mar 15, 2022  
 3 months post #Pfizer booster. Constant chest pain and exercise intolerance for three months. EKG today was again abnormal after leveling off about a month ago. Inflammation is repeatedly spreading to my heart. Myo/pericarditis is not a mild condition. #VaccineSideEffects



BOILING, CHRISTINA  
 16 Mar 2022 9:17:47  
 Shores  
 Female  
 Vital signs  
 PE normal  
 QRS complex  
 QT/QTc  
 P-R-T axis  
 75 bpm  
 104 mm  
 35 ms  
 354/402 ms  
 97° -128° -134°  
 Serial sinus rhythm  
 ST-T wave abnormality, consider inferior ischemia  
 Abnormal EKG  
 Technician: HARRISS  
 Order no. 700424704  
 User: fmed

COMMENT:  
 EKG shows a regular sinus rhythm with ST-T wave abnormalities, consider inferior ischemia. Abnormal EKG.

Dec. 31, 2021 - 18-year old Runa Cody, an Italian boy who was studying in the UK, died suddenly on Dec. 31, 2021 from pericarditis one month after second COVID-19 vaccine. ([click here](#))



Andrea  
Zambrano

The battle of Doina, mother courage who asks for truth for the death of her 18-year-old son, Runa Cody: « **The autopsy revealed a fatal pericarditis, had made the vaccine just a month earlier** ». But the Civitavecchia gip filed the report for manslaughter because at the time there was not enough scientific literature. But that's not true: « The cases were known as early as June 2021 ». « I will go all the way, I want to have the heart we have kept analyzed ».



*"It should also be stressed that at the time of administration and also at present, the scientific literature on the subject was extremely scarce or absent, and that the pandemic situation was of absolute gravity. So, the responsibility of anyone on the subjective level would not be conceivable".* This disconcerting sentence is found in the sentence with which the judge for the preliminary investigations of Civitavecchia Paola Petti rejects the opposition to the request to close the report for manslaughter against unknown persons on the case by **Runa Cody, who died at 18 years of age from fulminant perimycocarditis one month after covid vaccination.**

**The sentence bears the date of March 23**, but was made known in recent days by the young man's mother, Doina Marchetti, who for more than a year and a half has been fighting to obtain the truth about the unexpected death of her son.

**Disconcerting, because the medical literature available on post-vaccine myocarditis** not only is it ascertained "currently", but it was also "at the time of administration" of the Pfizer vaccine made by the boy in England in September and November 2021.

Jan. 2022 – Toronto lawyer Adam Goodman had pericarditis and cardiac tamponade after second dose of Pfizer but insisted on getting a booster ([click here](#))

# I was hospitalized because of a COVID-19 vaccine side effect, but that didn't stop me from getting a booster

---

ADAM GOODMAN

CONTRIBUTED TO THE GLOBE AND MAIL

PUBLISHED JANUARY 10, 2022

UPDATED JANUARY 11, 2022

---

*Adam Goodman is a lawyer in Toronto.*

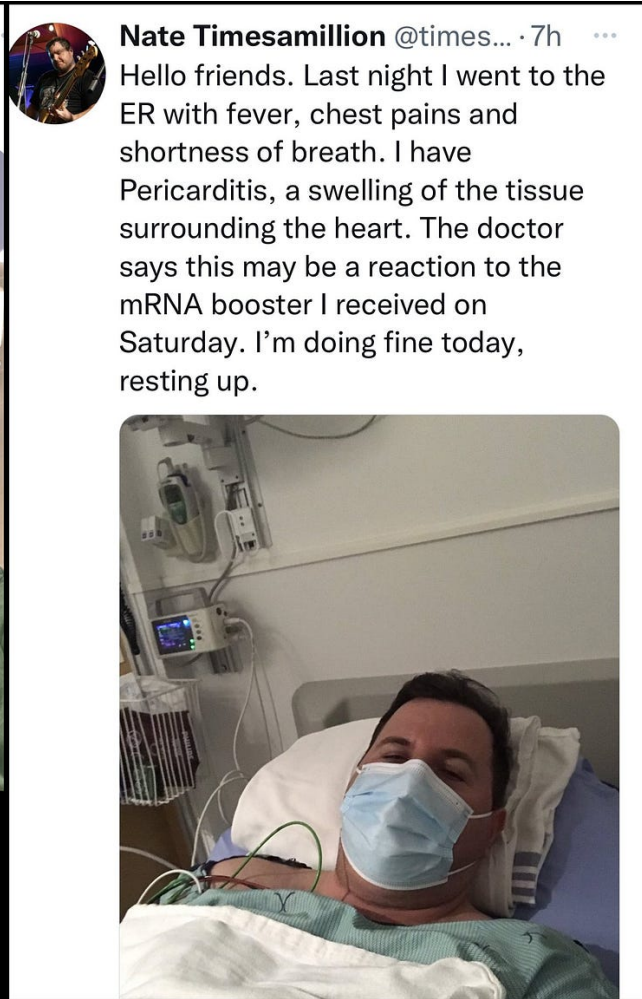

After receiving my second dose of Pfizer, I developed what I thought was muscle pain that started in my neck and spread to my chest. After consulting with my personal doctor, I learned that I had developed one of the two potential significant side effects associated with the mRNA vaccines – pericarditis, an inflammation of the lining that surrounds the heart. The other side effect, myocarditis, is an inflammation of the heart itself. Other typical side effects associated with viral-vector vaccines include syndromes causing blood clots.

Because I thought I was experiencing muscle pain, I let the pericarditis go too long without treatment. As a result, I experienced a dangerous squeezing of the heart called tamponade. I spent five days in hospital recovering with the help of a crack team of cardiologists, nurses and pharmacists at Toronto's University Health Network and a heavy dose of anti-inflammatory drugs.

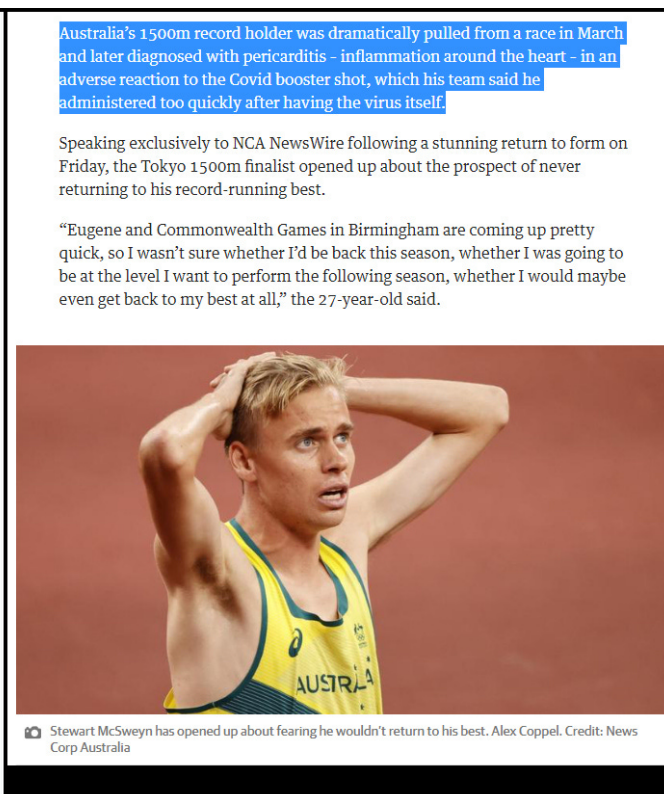
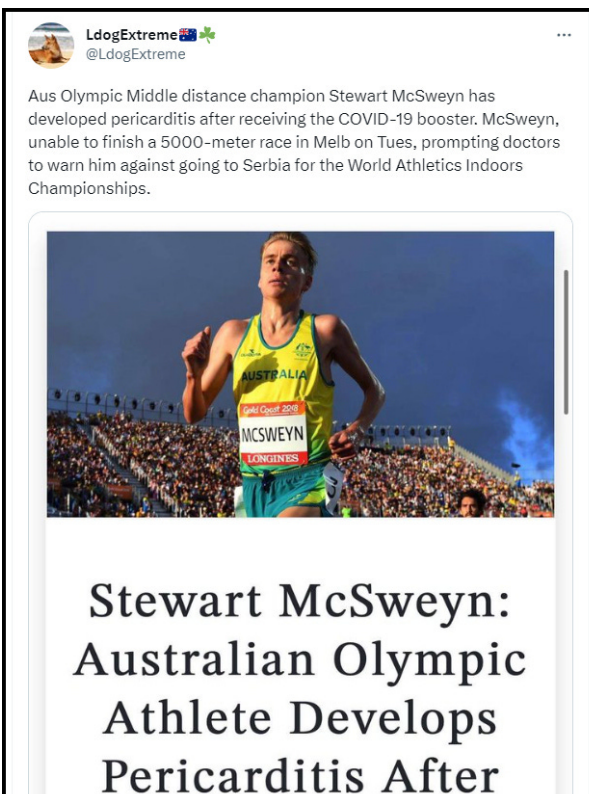---

Furthermore, I accept my role as collateral damage of the vaccine rollout. Before the current Omicron wave, vaccines helped us get back to some degree of normality. They protect society and our public-health system. Previous generations were asked to undertake far greater risks for the protection of society, including being drafted for war. The vaccines are our civic duty.

Feb. 2022 – BC Musician “Nate Timesamillion” developed pericarditis three days after his COVID-19 mRNA booster shot & was hospitalized




March 2022 – 27-year old Australian 1500m record holder Stewart McSweyn was dramatically pulled out of a 5000m race and was diagnosed with pericarditis ([click here](#))






Dec. 22, 2022 – 26-year old Swiss Olympic Sprinter had a Pfizer mRNA booster shot on Dec. 22, 2022 and five days later developed pericarditis ([click here](#))

### Swiss sprinter Sarah Atcho diagnosed with pericarditis after Pfizer booster shot



An Olympic sprinter says she is "upset" at being diagnosed with a rare heart condition after getting her Pfizer booster shot.

 **Frank Chung**

 @franks\_chung  4 min read January 20, 2022 - 3:33PM



Sarah Atcho during the 2019 Summer Universiade in Naples, Italy. Picture: Ivan Romano/Getty Images

 **Sarah Atcho**  is at Tenerife Las Americas.

Yesterday at 6:28 PM · Adeje, Spain · 🌐

▲NEWS▲NEWS▲

Obviously as you know, I'm trying to be as transparent as I can and now is more important than ever.

On December 22 I got my booster vaccination because I didn't want to struggle with this when the season started. I was told that it was safer to get Pfizer (even though I had Moderna the first time) to avoid cardiac side effects.

On December 27 I felt a tightness in the chest and started feeling dizzy while walking up the stairs. This happened a few more times until I decided to check with a cardiologist who diagnosed me with pericarditis (inflammation of the thin membrane surrounding the heart).


I am now not allowed to get my heart rate up for a few weeks to allow my heart to rest and heal from the inflammation. I am still doing everything I can with my coach to keep my muscles moving and he's doing a GREAT job, thank you @patsaile !!

I have to admit that I am upset at the situation because we don't talk enough about the side effects. I feel helpless since this is completely out of my control...

I am glad the vaccine helped avoid many deaths and reduce the pressure on the hospitals and hospital staff however I am frustrated that myself as well as other young and healthy people are suffering from these heavy side effects.

I hope you understand why it is important for me to share, I'll keep you guys updated on the process 🙏

let me know if you're experiencing the same, let's help each other!

 @harvey.4h

March 20, 2023 – Japan – 14-year old girl Japanese girl died suddenly two days after third Pfizer COVID-19 mRNA vaccine dose. Cause of death: myopericarditis ([click here](#))

## A case of fatal multi-organ inflammation following COVID-19 vaccination

Hideyuki Nushida,<sup>a,\*</sup> Asuka Ito,<sup>a</sup> Hiromitsu Kurata,<sup>a,b</sup> Hitomi Umemoto,<sup>a,c</sup> Itsuo Tokunaga,<sup>a</sup> Hirofumi Iseki,<sup>a,b</sup> and Akiyoshi Nishimura<sup>a</sup>

► [Author information](#) ► [Article notes](#) ► [Copyright and License information](#) [Disclaimer](#)

### Abstract


[Go to: ►](#)

A 14-year-old Japanese girl died unexpectedly 2 days after receiving the third dose of the BNT1262b2 mRNA COVID-19 vaccine. Autopsy findings showed congestive edema of the lungs, T-cell lymphocytic and macrophage infiltration in the lungs, pericardium, and myocardium of the left atria and left ventricle, liver, kidneys, stomach, duodenum, bladder, and diaphragm. Since there was no preceding infection, allergy, or drug toxicity exposure, the patient was diagnosed with post-vaccination pneumonia, myopericarditis, hepatitis, nephritis, gastroenteritis, cystitis, and myositis. Although neither type of inflammation is fatal by itself, **arrhythmia is reported to be the most common cause of death in patients with atrial myopericarditis. In the present case, arrhythmia of atrial origin was assumed as the cause of cardiac failure and death.** In sudden post-vaccination deaths, aggressive autopsy systemic search and histological examination involving extensive sectioning of the heart, including the atrium, are indispensable.

**Keywords:** Systemic inflammation, Myopericarditis, COVID-19, Vaccines, Sudden death, Autopsy

March 2023 – British Columbia – In his 20s, Ayden Thane, a basketball player, developed pericarditis after COVID-19 vaccine in Sep. 2021. He has not recovered. ([click here](#))

## Ayden Thane



Breanna Thane is organizing this fundraiser on behalf of Courtney Thane.

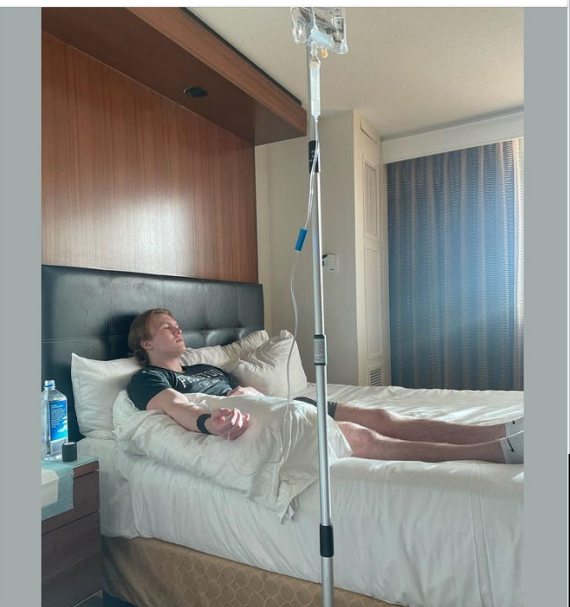
Hi, My name is Breanna Thane and I am starting this GoFundMe to help my little brother Ayden Thane. Ayden was diagnosed with **Myopericarditis and cellular/nerve damage caused by his covid-19 vaccine back in Sept 2021. He is one of the unfortunate ones who's pain and symptoms are not going away, and keep getting worse.** Over the last 19 months, we have tried everything we can to figure out what is going on in his body to help him get better, but nothing has worked. Medications, countless supplements, IV treatments,



Ayden Thane is with Courtney Thane in Las Vegas, NV, United States. ...

March 2 · 🌐

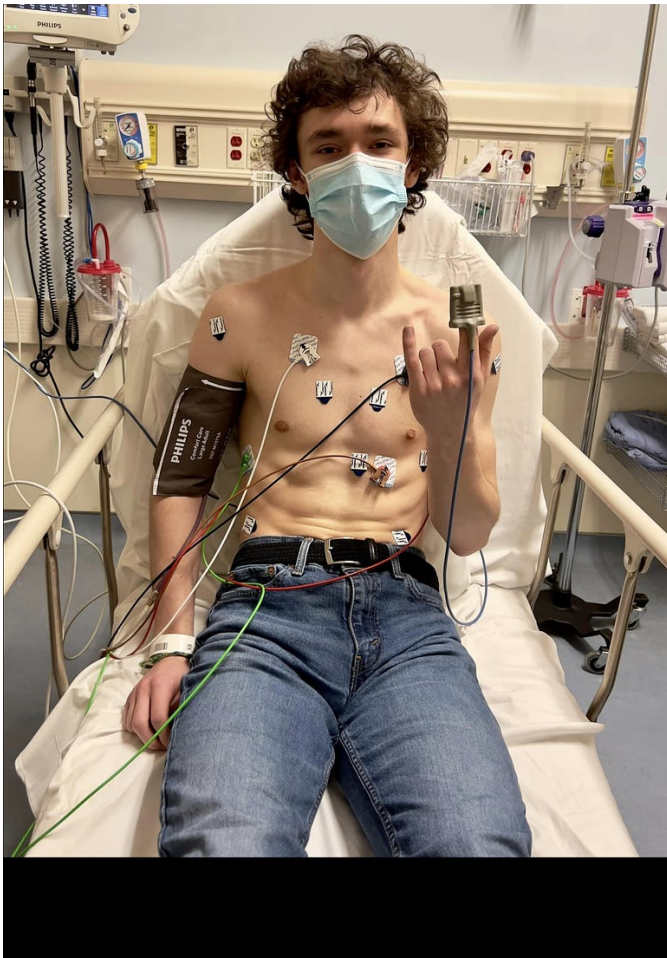Very grateful that after 19 months of hell and excruciating pain, I am able to get another opportunity at healing with this new treatment. I have not shared my story because of how bad my condition has been, but I will be sharing it once I am healed. As of now I am still focused on healing and will continue to push through at a chance of getting back to loving my life.



👍👍👍 82

18 comments 1 share

April 2023 – Kemptville, ON – 17-year old hockey player for the U18 Kemptville Royals, Vinnie Delorme had COVID-19 vaccines in 2021 & got pericarditis in Apr. 2023 ([click here](#))



**Jennifer Delorme**  
April 8 · 🌐

✨ OUR BIGGEST THANK YOU TO ALL OF YOU AND THE BEST NEWS POSSIBLE. 🙏❤️

Vinnie is stable and now home. He has more ECG's and Echograms this coming week and follow ups, but he feels so much better.

**It's a mystery:**

All we know at this point is that the lining/sack around his heart swelled incredibly which caused great duress to his heart. The Emerg doctors at both hospitals say they have never seen anything like it in a teenage boy. The pain was excruciating(yes he has since learned that his self proclaimed 4 out of 10 was actually a 10 on the face chart at CHEO!), his blood pressure dropping as low as 70/42, the seizures and passing out, flipping the bed back to rush the blood to his brain, us feeling completely helpless, his siblings all rallying together because that's all they know how to do, heart rate dropping as low as 21 and all still, cause unknown. 🤔🙏

\*Fun fact, one of the first questions we were asked was when was his last COVID vaccine... NOT that he may be sick and that being the cause of his issue, BUT that the vaccine may have caused the swelling. It's been two years, so that was ruled out although I now sit here still questioning it as so many doctors asked when he had the vaccine and I have a friend who experienced that post vaccine.



## My Take...

Pericarditis is an inflammation of the pericardium, which is a thin, protective membrane surrounding the heart.

Myocarditis (inflammation of the heart muscle) is very common after COVID-19 mRNA vaccination, as common as 1:30 per one mRNA dose. One study suggests post COVID-19 vaccine myocarditis is 2.5 times as common as pericarditis ([click here](#)).

WHO's VigiAccess database lists 28,328 reports of myocarditis and 23,173 reports of pericarditis for ALL COVID-19 vaccines ([click here](#))

Here are some key points:

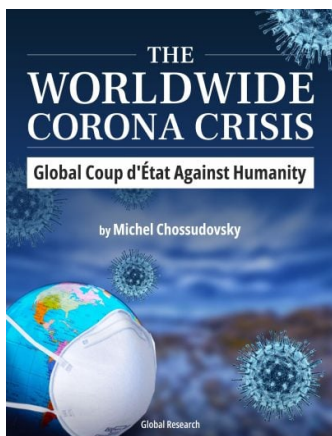
- COVID-19 vaccine pericarditis affects young men and young women;
- Pericarditis is slightly less common than myocarditis;
- Pericarditis can result in long term permanent disability;
- Those who suffer long term due to pericarditis can't find treatments;
- Pericarditis can also be fatal, as happened in 2 cases here: a 14 year old Japanese girl and an 18 year old Italian boy studying in the UK.

\*

Note to readers: Please click the share button above. Follow us on Instagram and Twitter and subscribe to our Telegram Channel. Feel free to repost and share widely Global

Research articles.

*Dr. William Makis is a Canadian physician with expertise in Radiology, Oncology and Immunology. Governor General's Medal, University of Toronto Scholar. Author of 100+ peer-reviewed medical publications.*



## The Worldwide Corona Crisis, Global Coup d'Etat Against Humanity

by Michel Chossudovsky

Michel Chossudovsky reviews in detail how this insidious project “destroys people’s lives”. He provides a comprehensive analysis of everything you need to know about the “pandemic” — from the medical dimensions to the economic and social repercussions, political underpinnings, and mental and psychological impacts.

*“My objective as an author is to inform people worldwide and refute the official narrative which has been used as a justification to destabilize the economic and social fabric of entire countries, followed by the imposition of the “deadly” COVID-19 “vaccine”. This crisis affects humanity in its entirety: almost 8 billion people. We stand in solidarity with our fellow human beings and our children worldwide. Truth is a powerful instrument.”*

ISBN: 978-0-9879389-3-0, Year: 2022, PDF Ebook, Pages: 164, 15 Chapters

We encourage you to support the eBook project by making a donation through Global Research’s [DonorBox “Worldwide Corona Crisis” Campaign Page](#).

The original source of this article is [COVID Intel](#)  
Copyright © [Dr. William Makis](#), [COVID Intel](#), 2023

**[Comment on Global Research Articles on our Facebook page](#)**

**[Become a Member of Global Research](#)**

Articles by: [Dr. William Makis](#)

**Disclaimer:** The contents of this article are of sole responsibility of the author(s). The Centre for Research on Globalization will not be responsible for any inaccurate or incorrect statement in this article. The Centre of Research on Globalization grants permission to cross-post Global Research articles on community internet sites as long the source and copyright are acknowledged together with a hyperlink to the original Global Research article. For publication of Global Research articles in print or other forms including commercial internet sites, contact: [publications@globalresearch.ca](mailto:publications@globalresearch.ca)

[www.globalresearch.ca](http://www.globalresearch.ca) contains copyrighted material the use of which has not always been specifically authorized by the copyright owner. We are making such material available to our readers under the provisions of "fair use" in an effort to advance a better understanding of political, economic and social issues. The material on this site is distributed without profit to those who have expressed a prior interest in receiving it for research and educational purposes. If you wish to use copyrighted material for purposes other than "fair use" you must request permission from the copyright owner.

For media inquiries: [publications@globalresearch.ca](mailto:publications@globalresearch.ca)