

COVID mRNA Vaccines and Pregnancy: Congenital Malformations Caused by Pfizer & Moderna COVID-19 mRNA Vaccines

Malformations of the heart, brain, limbs, abdomen and more horror stories.

By [Dr. William Makis](#)

Theme: [Science and Medicine](#)

Global Research, June 18, 2023

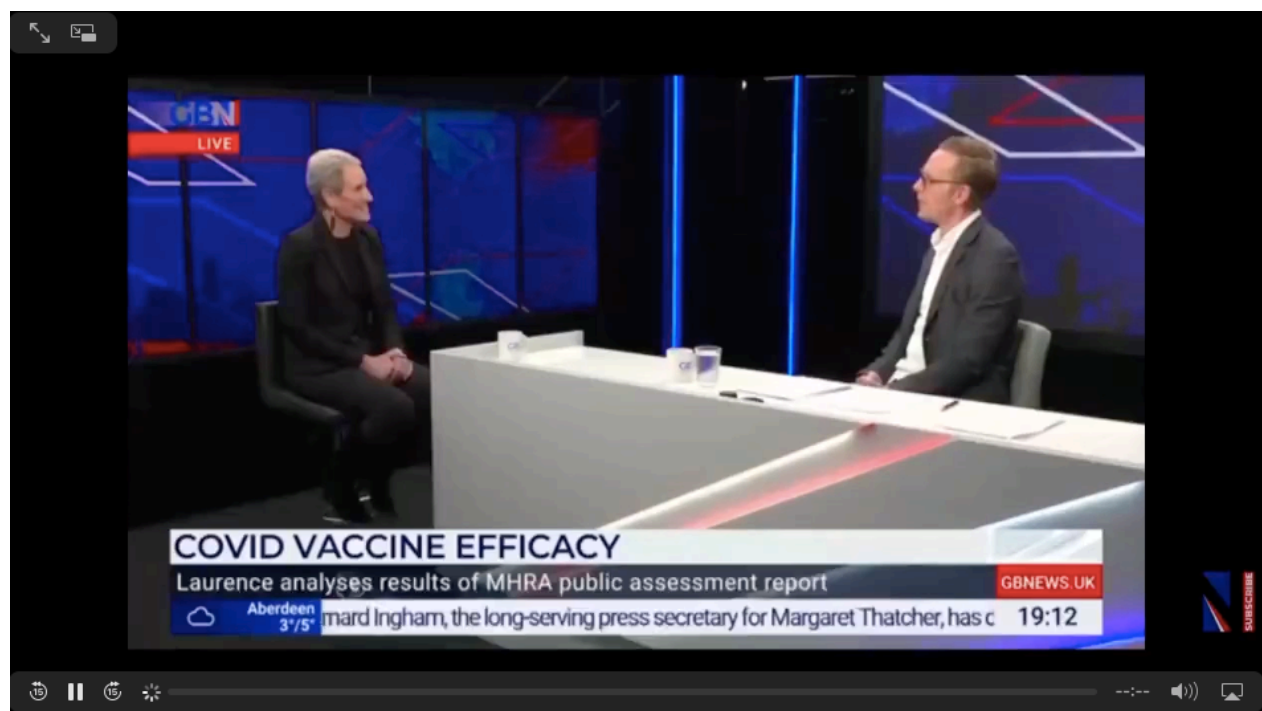
[COVID Intel](#) 17 June 2023

All Global Research articles can be read in 51 languages by activating the Translate Website button below the author's name.

To receive Global Research's Daily Newsletter (selected articles), [click here](#).

Click the share button above to email/forward this article to your friends and colleagues. Follow us on [Instagram](#) and [Twitter](#) and subscribe to our [Telegram Channel](#). Feel free to repost and share widely Global Research articles.

Pfizer and Moderna didn't do any studies in pregnant women (Dr. Tina Peers):



[Click here to view the video](#)

What types of congenital malformations do Pfizer and Moderna cause?

We don't hear much about this topic so I felt it would be interesting to take a deeper dive into the types of congenital malformations that have been documented with Pfizer and Moderna COVID-19 mRNA vaccines.

I would like to thank Substack author "WelcomeTheEagle88" for his work on finding these VAERS reports, please check out his substack, he has done some incredible work ([click here](#))

[CASE 1 \(VAERS 1829815\)](#) - 33-year-old pregnant woman took 1st Pfizer dose at 3wk6d of pregnancy, fetus developed congenital limb malformations


Vaccinated on Jun. 28, 2021, abortion on Sep. 4, 2021 for severe limb malformations: hypoplastic upper extremities, bony agenesis of long bones, symmbrachydactyly - three fingers on each hand, radial zamba hand.

VAERS ID: 1829815	Vaccinated: 2021-06-28
VAERS Form: 2	Onset: 2021-06-28
Age:	Submitted: 0000-00-00
Sex: Unknown	Entered: 2021-10-29
Location: Foreign	

Vaccination / Manufacturer (1 vaccine)	Lot / Dose	Site / Route
COVID19: COVID19 (COVID19 (PFIZER-BIONTECH)) / PFIZER/BIONTECH	FE1248 / 1	- / OT


Administered by: Other **Purchased by:** ??
Symptoms: Blood immunoglobulin G, Blood immunoglobulin M, Chromosomal analysis, Karyotype analysis, Limb malformation, Rubella antibody test, Autopsy, Toxoplasma serology, Antibody test, Maternal exposure during pregnancy
Life Threatening? No
Birth Defect? Yes
Died? Yes
Date died: 2021-08-02
Permanent Disability? No
Recovered? No
Office Visit (V2.0)? No
ER or Office Visit (V1.0)? No
ER or ED Visit (V2.0)? No
Hospitalized? No
Previous Vaccinations:
Other Medications:
Current Illness:
Preexisting Conditions:
Allergies:
Diagnostic Lab Data: Test Date: 20210806; Test Name: AC.C. TIROPEROXIDASE; Result Unstructured Data: Test Result:37.87 IU/ml; Test Date: 2021; Test Name: Autopsy; Result Unstructured Data: Test Result:Hypoplastic upper extremities; Comments: Hypoplastic upper extremities, with bony agenesis of long bones frontbrach, symmbrachydactyly (three fingers on each hand) and radial zamba hand; Test Date: 20210806; Test Name: Ig G ANTI TOXOPLASMA G; Result Unstructured Data: Test Result:650.0 IU/ml; Test Date: 20210806; Test Name: AC. IgM ANTI-TOXOPLASMA G; Test Result: Positive ; Test Date: 2021; Test Name: CGH arrays; Result Unstructured Data: Test Result:Normal; Comments: Normal CGH arrays; Test Date: 2021; Test Name: karyotype XY; Result Unstructured Data: Test Result:Normal; Comments: Normal karyotype XY; Test Date: 20210806; Test Name: SEROL. RUBELLA IgG; Test Result: Positive ; Test Date: 20210806; Test Name: IgG TOXOPLASMA(AVIDNESS); Result Unstructured Data: Test Result:0.72
CDC 'Split Type': ESPFIZER INC202101432998
Write-up: Drug exposure during pregnancy, first trimester; Congenital limb malformation NOS This is a spontaneous report from a contactable physician downloaded from the regulatory authority with regulatory authority number ES-AEMPS-1018335. This is the first of two reports. This physician reported information for both mother and fetus. This is a fetus report. A 33-year-old female pregnant mother (3-week-old patient of an unspecified gender) received bnt162b2 (COMIRNATY) dose 1 (age of 3-week-old) intramuscularly (patient via transplacental) on 28Jun2021 (Lot Number: FE1248) as dose 1, single for covid-19 immunisation. The patient's medical history and concomitant medications were not reported. On 28Jun2021, the patient experienced drug exposure during pregnancy, first trimester and congenital limb malformation nos with seriousness criterion of congenital anomaly, medically significant and death. The patient received treatment for the adverse events. It was further reported that the mother was vaccinated at week 3+6 of amenorrhea. The mother had legal termination of pregnancy performed on 04Sep2021 for severe malformations. Postabortion review of the normal patient autopsy (2021). Hypoplastic upper extremities, with bony agenesis of long bones frontbrach, symmbrachydactyly (three fingers on each hand) and radial zamba hand. Normal karyotype XY (2021). Normal CGH arrays (2021). The mother underwent therapeutic abortion with fetal outcome is congenital anomaly. The patient underwent lab tests and procedures on 06Aug2021 which included AC.C. Tiroperoxidase (antibody test) was 37.87 iu/ml; IgG Anti Toxoplasma G (blood immunoglobulin G) was 650.0 iu/ml; AC. IgM Anti-Toxoplasma G (blood immunoglobulin m) was positive; Serol. Rubella IgG (rubella antibody test) was positive; and IgG Toxoplasma (Avidness) (toxoplasma serology) was 0.72. The patient died on 02Aug2021. An autopsy was performed that revealed top on medical grounds (abortion induced).; Sender's Comments: Linked Report(s) : ES-PFIZER INC-202101449133 mother/fetus; Reported Cause(s) of Death: congenital limb malformation nos; Autopsy-determined Cause(s) of Death: TOP on medical grounds

A similar case posted by Anthony Dionne on Twitter:




Anthony Dionne 🐦

une de mes cousine s'est fait vacciner pendant sa grossesse .. son bébé est né il y a 3-4 jours .. avec une main comme ça .. les infirmières lui ont assuré/confirmé que c'était à cause du vaccin .. que depuis que les femmes enceintes se font vacciner pendant la grossesse qu'ils voient des bébés avec des membres manquants/ handicaps comme ça à chaque jour !!!



À l'instant l'aime... ondra

In France. Newborn with missing fingers. The mother was vaccinated during pregnancy. The nurses confirmed to her that it was vaccine related as they have seen more and more newborns with missing limbs!




Youmzain and the fourth h... ...
@Youmzain4

🌟 Pfizer reproductive tox studies in pregnant rats: "There was an increase(~2x)of pre-implantation (pregnancy) loss"and,"a very low incidence of gastroschisis, mouth/jaw malformations, right sided aortic arch, and cervical vertebrae abnormalities." THERE'S NO HUMAN SAFETY STUDY 🌟

3:41 AM · Aug 20, 2021

8 Retweets 1 Quote 4 Likes

💬 ↺ ❤️ 📌 ⬆️ ⚠️ Tip

 Tweet your reply! [Reply](#)

[Show more replies](#)

What is radial zamba hand?

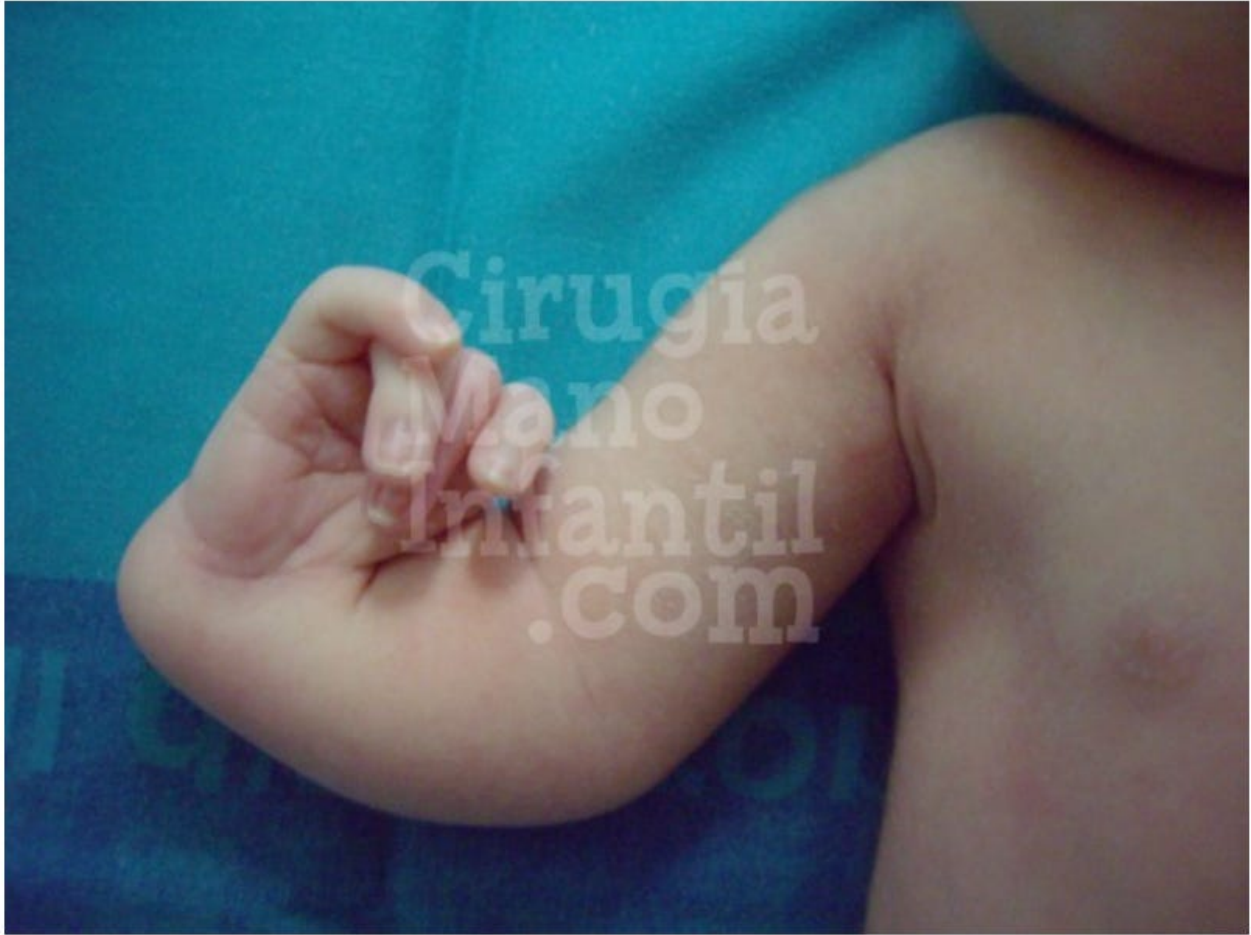

Figure 5. Radial clubhand. The hand is skewed, the forearm is very short and there is no thumb.

[CASE 2 \(VAERS 1895184\)](#) – A pregnant woman had 2nd Pfizer dose on Aug. 23, 2021 at 4wk, Oct. 23, 2021 U/S showed CNS malformations (missing brain tissue, hydrocephalus). The fetus died at an unknown date.

VAERS ID: 1859184 **Vaccinated:** 2021-08-23
VAERS Form: 2 **Onset:** 2021-08-23
Age: **Submitted:** 0000-00-00
Sex: Unknown **Entered:** 2021-11-10
Location: Foreign

Vaccination / Manufacturer (1 vaccine)	Lot / Dose	Site / Route
COVID19: COVID19 (COVID19 (PFIZER-BIONTECH)) / PFIZER/BIONTECH	UNKNOWN / 2	- / OT

Administered by: Other **Purchased by:** ??

Symptoms: Congenital central nervous system anomaly, Congenital hydrocephalus, Ultrasound scan, Foetal exposure during pregnancy, Maternal exposure during pregnancy

Life Threatening? No

Birth Defect? Yes

Died? Yes

Date died: 0000-00-00

Permanent Disability? No

Recovered? No

Office Visit (V2.0)? No

ER or Office Visit (V1.0)? No

ER or ED Visit (V2.0)? No

Hospitalized? No

Previous Vaccinations:

Other Medications:

Current Illness:

Preexisting Conditions:

Allergies:

Diagnostic Lab Data: Test Date: 20211023; Test Name: Ultrasound scan; Result Unstructured Data: Test Result: CNS malformation seen as missing brain tissue; Test Date: 20211023; Test Name: Ultrasound scan; Result Unstructured Data: Test Result: CNS malformation and hydrocephalus; Comments: 1st trimester

CDC 'Split Type': DKPFIZER INC202101540717

Write-up: Fetus with CNS malformation. Accurate diagnosis is not known; hydrocephalus; Maternal Exposure During Pregnancy, first trimester; Fetal exposure during pregnancy, first trimester; This is a spontaneous report from a contactable physician. This is the second of two reports. The first report is downloaded from the Regulatory Authority, regulatory authority number DK-DKMA-WBS-0090592. This physician reported information for both mother and foetus. This is the fetus report. Only this case is serious. A fetus patient of an unspecified gender received BNT162B2 (COMIRNATY), via transplacental route on 23Aug2021 (Batch/Lot Number: Unknown) as dose 2, single for COVID-19 immunization. The fetus patient medical history and concomitant medication was not reported. The mother's historical vaccine included BNT162B2 (COMIRNATY), intramuscular on an unspecified date (Batch/Lot Number: Unknown) as dose 1, single for COVID-19 immunization. The mother had her last menstrual period on 28Jul2021. On 23Aug2021, the mother was vaccinated with the second dose. On 25Aug2021, the mother had a positive pregnancy test. On 23Oct2021, the fetus patient was diagnosed with CNS congenital anomaly due to 1 trimester scan. The patient had fetal exposure during pregnancy at the first trimester, and experienced CNS malformation but accurate diagnosis was not known. The patient underwent lab tests and procedures on 23Oct2021 which included first trimester ultrasound scan that showed CNS malformation and hydrocephalus. CNS malformation seen as missing brain tissue. The adverse events were reported as serious for fatal outcome and resulting in birth defect or congenital anomaly. The fetus patient died on an unspecified date in 2021 due to CNS congenital anomaly, the precise date of death was not reported. An autopsy was not performed. The physician stated that it was unknown if there was a causal relation between the events and BNT162B2. No follow-up attempts are possible; information about lot/batch number cannot be obtained. No further information is expected.; Sender's Comments: Linked Report(s) : DK-PFIZER INC-202101531056 maternal/fetus case; Reported Cause(s) of Death: CNS congenital anomaly; fetal exposure during pregnancy, first trimester; maternal exposure during pregnancy, first trimester; hydrocephalus congenital

CASE 3 (VAERS 1969351) – 36 year old mother had 2nd Pfizer jab Jun. 17, 2021 at 1wk of pregnancy. U/S on Jul. 29, 2021 showed cardiac malformation, fetus died Aug. 6, 2021, patient had abortion.

VAERS ID: 1969351 **Vaccinated:** 2021-06-17
VAERS Form: 2 **Onset:** 2021-07-29
Age: **Submitted:** 0000-00-00
Sex: Unknown **Entered:** 2021-12-22
Location: Foreign

Vaccination / Manufacturer (1 vaccine)	Lot / Dose	Site / Route
COVID19: COVID19 (COVID19 (PFIZER-BIONTECH)) / PFIZER/BIONTECH	FD0168 / 2	- / OT

Administered by: Other **Purchased by:** ??

Symptoms: Heart disease congenital, Ultrasound scan, Cardiac disorder, Maternal exposure during pregnancy

Life Threatening? No

Birth Defect? Yes

Died? Yes

Date died: 0000-00-00

Permanent Disability? No

Recovered? No

Office Visit (V2.0)? No

ER or Office Visit (V1.0)? No

ER or ED Visit (V2.0)? No

Hospitalized? No

Previous Vaccinations:

Other Medications:

Current Illness:

Preexisting Conditions:

Allergies:

Diagnostic Lab Data: Test Date: 20210729; Test Name: ultrasound; Result Unstructured Data: Test Result:cardiac malformation in the fetus; Test Date: 20210806; Test Name: ultrasound; Result Unstructured Data: Test Result:revealing the death of the fetus

CDC 'Split Type': FRPFIZER INC202101782465

Write-up: Maternal exposure during pregnancy, first trimester; Heart malformation; heart defect. This is a spontaneous report received from contactable reporter(s) (Consumer or other non-HCP and Other HCP) from the Regulatory Authority. Regulatory number: FR-AFSSAPS-PC20215309 (Regulatory Authority). A fetus patient was exposed to bnt162b2 (COMIRNATY), transplacental (mother's route: intramuscular) administration date 17Jun2021 (Lot number: FD0168) as dose 2, single for covid-19 immunisation. The mother of the patient was 36-year-old. The mother's relevant medical history included: "3 gestations 2 deliveries" (unspecified if ongoing); "3 gestations 2 deliveries" (unspecified if ongoing). Date of last menstrual period of the mother: 04Jun2021. The mother was 1 weeks pregnant at the time of exposure to bnt162b2. The mother was 8 weeks pregnant at the event onset. The mother is expected to deliver one baby(s) on 11Mar2022. The mother's concomitant medications were not reported. Vaccination history included: Covid-19 vaccine (dose 1, MANUFACTURER UNKNOWN), for COVID-19 immunisation. The mother's vaccination history included: Covid-19 vaccine (dose 1, MANUFACTURER UNKNOWN), for Covid-19 immunisation. The following information was reported: MATERNAL EXPOSURE DURING PREGNANCY (death, congenital anomaly), outcome "fatal", described as "Maternal exposure during pregnancy, first trimester"; HEART DISEASE CONGENITAL (death, congenital anomaly) with onset 29Jul2021, outcome "fatal", described as "Heart malformation"; CARDIAC DISORDER (death, congenital anomaly) with onset 29Jul2021, outcome "fatal", described as "heart defect". The pregnancy resulted in still birth. The fetal outcome is intrauterine death. The patient underwent the following laboratory tests and procedures: ultrasound scan: (29Jul2021) cardiac malformation in the fetus: (06Aug2021) revealing the death of the fetus. On 20Jun2021, discovery of a third pregnancy (3 gestations 2 deliveries). On 06Aug2021, performing a second ultrasound revealing the death of the fetus and subsequent initiation of a medical abortion. Discovery of a heart defect in a fetus which led to its death 6 weeks after the discovery of pregnancy, on Day 42 of the administration of Dose 2 of the COMIRNATY vaccine to its mother. The patient date of death was unknown. The reported cause of death was maternal exposure during pregnancy, heart disease congenital, cardiac disorder. It was not reported if an autopsy was performed.; Sender's Comments: Linked Report(s) : FR-PFIZER INC-202101794064 Mother/fetus case; Reported Cause(s) of Death: Heart malformation; heart defect; Maternal exposure during pregnancy, first trimester

CASE 4 (VAERS 2027338) – Pregnant woman had 1st Moderna dose at 2wk pregnancy, fetus developed cardiac malformations – transposition of great arteries and tricuspid valve incompetence, baby was born and died at 3 months old.

VAERS ID: 2027338 Vaccinated: 2020-12-23
VAERS Form: 2 Onset: 2020-12-23
Age: Submitted: 0000-00-00
Sex: Male Entered: 2022-01-12
Location: Florida

Vaccination / Manufacturer (1 vaccine)	Lot / Dose	Site / Route
COVID19: COVID19 (COVID19 (MODERNA)) / MODERNA	025J20A / 1	- / OT

Administered by: Unknown Purchased by: ??

Symptoms: Transposition of the great vessels, Tricuspid valve incompetence Foetal exposure during pregnancy

Life Threatening? No

Birth Defect? Yes

Died? Yes

Date died: 2021-11-24

Permanent Disability? No

Recovered? No

Office Visit (V2.0)? No

ER or Office Visit (V1.0)? No

ER or ED Visit (V2.0)? No

Hospitalized? No

Previous Vaccinations:

Other Medications:

Current Illness:

Preexisting Conditions: Medical History/Concurrent Conditions: Maternal exposure during pregnancy (in the time frame in which the heart was forming in utero.)

Allergies:

Diagnostic Lab Data:

CDC 'Split Type': USMODERNATX, INC.MOD20213

Write-up: Transposition of the great arteries (LTGA)/ Baby born with LTGA; Mild and moderate/Tricuspid regurgitation; foetal exposure during pregnancy; This case was initially received via an unknown source (no reference has been entered for a health authority or license partner) on 10-Nov-2021. The most recent information was received on 23-Dec-2021 and was forwarded to Moderna on 23-Dec-2021. This case was initially received via an unknown source (no reference has been entered for a health authority or license partner) on 10-Nov-2021. The most recent information was received on 23-Dec-2021 and was forwarded to Moderna on 23-Dec-2021. This spontaneous case was reported by a consumer and describes the occurrence of TRANSPOSITION OF THE GREAT VESSELS (Transposition of the great arteries (LTGA)/ Baby born with LTGA) and TRICUSPID VALVE INCOMPETENCE (Mild and moderate/Tricuspid regurgitation) in a 3-month-old male patient who received mRNA-1273 (Moderna COVID-19 Vaccine) (batch no. 025J20A) for COVID-19 vaccination. The occurrence of additional non-serious events is detailed below. MEDICAL HISTORY (Parent): On 27-Jul-2021 lab test was done Fetal echo with result: L-TOA (abnormal) On an unknown date, Fetal non-stress test was done with result: normal (multiple throughout the pregnancy to monitor movement) and also test ultrasound fetoe test was done with result: biophysical profile to monitor growth normal findings baby was small On an unknown date in 2021, pregnancy test was done with result: positive On 19-Jul-2021, abdominal ultrasound test was done with result: abnormal (congenitally corrected L-transposition of the greater vessel) On an unknown date, the mother started taking Prenatal vitamins orally. The parent received the Moderna vaccine during the time that the heart was forming. It was also reported that other children were being tested on 10-Dec-2021, and were confirmed to have no heart defects. Her husband and as well the mother got tested for any genetic markers and waiting for the results which might take about 8 weeks. That type of heart anomaly was not one to be associated with genetic markers. The mother's past medical history included Maternal exposure during pregnancy on 23-Dec-2020. Previously administered products included for Product used for unknown indication: ASA (Dose: 85 mg and Route: PO (oral)) from 04-Aug-2021 to 20-Aug-2021. Concurrent medical conditions included Drug allergy. MEDICAL HISTORY (Patient): The patient's past medical history included Maternal exposure during pregnancy (in the time frame in which the heart was forming in utero.) on 23-Dec-2020. On 23-Dec-2020, the patient received first dose of mRNA-1273 (Moderna COVID-19 Vaccine) (Transplacental) 1 dosage form. On 23-Dec-2020, the patient experienced FOETAL EXPOSURE DURING PREGNANCY (foetal exposure during pregnancy). On 02-Jun-2021, the patient experienced TRANSPOSITION OF THE GREAT VESSELS (Transposition of the great arteries (LTGA)/ Baby born with LTGA) (seriousness criteria death, medically significant and congenital anomaly) and TRICUSPID VALVE INCOMPETENCE (Mild and moderate/Tricuspid regurgitation) (seriousness criteria medically significant and congenital anomaly). The patient died on 24-Nov-2021. The reported cause of death was transposition of the great arteries (ltga)/ baby born with ltga. An autopsy was not performed. At the time of death, TRICUSPID VALVE INCOMPETENCE (Mild and moderate/Tricuspid regurgitation) had not resolved and FOETAL EXPOSURE DURING PREGNANCY (foetal exposure during pregnancy) had resolved. mRNA-1273 (Moderna COVID-19 Vaccine) (Transplacental) was withdrawn on an unknown date. No concomitant and treatment medication were provided. Company comment: This spontaneous case concerns a 3-month-old, male patient with Fetal Exposure During Pregnancy (approximately at 2 weeks of gestational age, transplacental exposure) to the first dose of mRNA-1273 vaccine, who was born with transposition of the great vessels (Transposition of the great arteries (LTGA)) and tricuspid valve incompetence (mild and moderate/tricuspid regurgitation) and died due to transposition of the great vessels at 3 months of age. An autopsy was not performed. During pregnancy, an anatomical scan had confirmed a diagnosis of congenitally L-transposition of the greater artery. The child was born by vaginal delivery and was full term with the mentioned congenital anomalies. The mother had two older children with no congenital anomalies, the reporter informed that genetic testing showed no relationship to the baby's diagnosis to the parents and genetic tests and other evaluations were ongoing at the time of the follow-up report. The benefit-risk relationship of mRNA-1273 vaccine is not affected by this report. Case was assessed as serious due to important medical event, congenital anomaly and death. This spontaneous case concerns a 3-month-old, male patient with Fetal Exposure During Pregnancy (approximately at 2 weeks of gestational age, transplacental exposure) to the first dose of mRNA-1273 vaccine, who was born with transposition of the great vessels (Transposition of the great arteries (LTGA)) and tricuspid valve incompetence (mild and moderate/tricuspid regurgitation) and died due to transposition of the great vessels at 3 months of age. Autopsy reported Transposition of the great arteries (LTGA)/ Baby born with LTGA as the cause of death. During pregnancy, an anatomical scan had confirmed a diagnosis of congenitally L-transposition of the greater artery. The child was born by vaginal delivery and was full term with the mentioned congenital anomalies. The mother had t This case was linked to MOD-2021-223997 (Parent-Child Link). See case MOD-2021-223997 for details regarding the child case. Most recent FOLLOW-UP information incorporated above includes: On 23-Dec-2021: Significant follow up received on 23-Dec-2021: Patient's Death date, autopsy details, Suspect batch number, onset date and end date for the event (Anomaly heart) were added and reporter causality of all events except foetal exposure during pregnancy updated (previously not provided).; Sender's Comments: This spontaneous case concerns a 3-month-old, male patient with Fetal Exposure During Pregnancy (approximately at 2 weeks of gestational age, transplacental exposure) to the first dose of mRNA-1273 vaccine, who was born with transposition of the great vessels (Transposition of the great arteries (LTGA)) and tricuspid valve incompetence (mild and moderate/tricuspid regurgitation) and died due to transposition of the great vessels at 3 months of age. Autopsy reported Transposition of the great arteries (LTGA)/ Baby born with LTGA as the cause of death. During pregnancy, an anatomical scan had confirmed a diagnosis of congenitally L-transposition of the greater artery. The child was born by vaginal delivery and was full term with the mentioned congenital anomalies. The mother had two older children with no congenital anomalies, the reporter informed that genetic testing showed no relationship to the baby's diagnosis to the parents and genetic tests and other evaluations were ongoing at the time of the follow-up report. The benefit-risk relationship of mRNA-1273 vaccine is not affected by this report. Case was assessed as serious due to important medical event, congenital anomaly and death. For the events transposition of great arteries and tricuspid valve incompetence, the reporters assessment is that it is related to the vaccine.; Reported Cause(s) of Death: Transposition of the great arteries (LTGA)/ Baby born with LTGA

CASE 5 (VAERS 2003908) – A pregnant woman had 2nd Pfizer dose at 10 days of pregnancy. Ultrasound at 21 weeks showed univentricular heart, aorta hypoplasia. Doctors decide “heart disease not accessible to full repair) – medical termination of pregnancy at 24 weeks.

VAERS ID: 2003908 Vaccinated: 2021-06-28
 VAERS Form: 2 Onset: 2021-11-16
 Age: Submitted: 0000-00-00
 Sex: Unknown Entered: 2022-01-05
 Location: Foreign

Vaccination / Manufacturer (1 vaccine)	Lot / Dose	Site / Route
COVID19: COVID19 (COVID19 (PFIZER-BIONTECH)) / PFIZER/BIONTECH	EX7823 2	- / OT

Administered by: Other Purchased by: ??

Symptoms: Heart disease congenital, Ultrasound scan, Univentricular heart, Aorta hypoplasia, Investigation, Maternal exposure during pregnancy

Life Threatening? No

Birth Defect? Yes

Died? Yes

Date died: 2021-11-01

Permanent Disability? No

Recovered? No

Office Visit (V2.0)? No

ER or Office Visit (V1.0)? No

ER or ED Visit (V2.0)? No

Hospitalized? No

Previous Vaccinations:

Other Medications:

Current Illness:

Preexisting Conditions:

Allergies:

Diagnostic Lab Data: Test Name: Cranio-caudal length; Result Unstructured Data: Test Result: 68.8mm; Comments: At 13 amenorrhea weeks + 4; Test Name: PAPP-A test; Result Unstructured Data: Test Result: 0.58MoM; Test Name: ultrasound; Result Unstructured Data: Test Result: does not find any malformation; Test Name: ultrasound; Result Unstructured Data: Test Result: severe heart defects

CDC 'Split Type': FRPFIZER INC202101866226

Write-up: Maternal exposure during pregnancy-first trimester; Single ventricle; Aorta hypoplasia; congenital anomaly of heart; This is a spontaneous report received from a contactable reporter(s) (Physician) from the Regulatory Authority. Regulatory number: FR-AESSAPS-AN20214738. A fetus patient was exposed to bnt162b2 (COMIRNATY), transplacental, administration date 28Jun2021 (Lot number: EX7823) as dose 2, single for covid-19 immunisation. Date of last menstrual period of the mother: 18Jun2021. The mother was 10 days pregnant at the time of exposure to bnt162b2. The mother was 21 weeks pregnant at the event onset. The mother is expected to deliver one baby(s) on 25Mar2022. The mother's relevant medical history and concomitant medications were not reported. The mother's vaccination history included: Comirnaty (Dose 1), administration date: 21May2021, for COVID-19 immunisation. The following information was reported: MATERNAL EXPOSURE DURING PREGNANCY (death, congenital anomaly), outcome "fatal", described as "Maternal exposure during pregnancy-first trimester"; UNIVENTRICULAR HEART (death, congenital anomaly) with onset 16Nov2021, outcome "fatal", described as "Single ventricle"; AORTA HYPOPLASIA (death, congenital anomaly) with onset 16Nov2021, outcome "fatal", described as "Aorta hypoplasia"; HEART DISEASE CONGENITAL (death, congenital anomaly) with onset 16Nov2021, outcome "fatal", described as "congenital anomaly of heart". The pregnancy resulted in therapeutic abortion. The fetal outcome is congenital anomaly. The patient underwent the following laboratory tests and procedures: investigation: 68.8mm, notes: At 13 amenorrhea weeks + 4; 0.58mom; ultrasound scan: does not find any malformation; severe heart defects. The patient date of death was Nov2021. The reported cause of death was heart disease congenital, univentricular heart, aorta hypoplasia. It was not reported if an autopsy was performed. Clinical course: Cardiopediatrician opinion in medical termination of pregnancy multidisciplinary cadre meeting (23Nov21) at 24 amenorrhea weeks + 3: severe complex cardio of the single left ventricle type with a single atrioventricular valve, hypoplasia of the aorta with subaortic conal septum and ejection port narrow. Heart disease not accessible to full repair. Medical termination of pregnancy in November 2021. CONCLUSION: Serious fetal heart defect (single left ventricle and hypoplasia of the aorta) requiring medical termination of pregnancy at 24 weeks, in a patient who received a second injection of COMIRNATY 10 days after the estimated start of pregnancy. No follow-up attempts are possible. No further information is expected.; Sender's Comments: Linked Report(s): FR-PFIZER INC-202101880583 Mother/Fetus case; Reported Cause(s) of Death: congenital anomaly of heart; Aorta hypoplasia; Single ventricle

CASE 6 (VAERS 2067674) – A pregnant woman had 1st Moderna COVID-19 mRNA vaccine on Aug. 15, 2021, at 3wk3d of pregnancy. Fetus developed malformations of the brain – agenesis of corpus callosum, asymmetrical and lack of brain structures, absence of septum pellucidum and fusion of the thalami, atresia of the 3rd ventricle.

VAERS ID: 2067674 **Vaccinated:** 2021-08-15
VAERS Form: 2 **Onset:** 0000-00-00
Age: **Submitted:** 0000-00-00
Sex: Unknown **Entered:** 2022-01-27
Location: Foreign

Vaccination / Manufacturer (1 vaccine)	Lot / Dose	Site / Route
COVID19: COVID19 (COVID19 (MODERNA)) / MODERNA	- 1	- / OT

Administered by: Unknown **Purchased by:** ??

Symptoms: Congenital brain damage

Life Threatening? No

Birth Defect? Yes

Died? Yes

Date died: 0000-00-00

Permanent Disability? No

Recovered? No

Office Visit (V2.0)? No

ER or Office Visit (V1.0)? No

ER or ED Visit (V2.0)? No

Hospitalized? No

Previous Vaccinations:

Other Medications:

Current Illness:

Preexisting Conditions: Medical History/Concurrent Conditions: Maternal exposure during pregnancy

Allergies:

Diagnostic Lab Data:

CDC 'Split Type': TNMODERNATX, INC.MOD20224

Write-up: Fusion of thalami (atresia of the third ventricle)/ brain abnormality: This spontaneous case was reported by a consumer and describes the occurrence of CONGENITAL BRAIN DAMAGE (Fusion of thalami (atresia of the third ventricle)/ brain abnormality) in a foetus patient of an unknown gender who received mRNA-1273 (COVID 19 Vaccine Moderna) for COVID-19 vaccination. MEDICAL HISTORY (Parent): On 23-AUG-2021 had a positive pregnancy test. On ??-OCT-2021 during pregnancy - pregnancy toxoplasmosis, German measles, diabetes tests were performed and were normal. MEDICAL HISTORY (Patient): The patient's past medical history included Maternal exposure during pregnancy on 15-Aug-2021. On 15-Aug-2021, the patient received first dose of mRNA-1273 (COVID 19 Vaccine Moderna) (Transplacental) 1 dosage form. On an unknown date, the patient experienced CONGENITAL BRAIN DAMAGE (Fusion of thalami (atresia of the third ventricle)/ brain abnormality) (seriousness criteria death and congenital anomaly). The reported cause of death was agenesis of the corpus callosum, asymmetrical and lack of brain structures, fusion of thalami (atresia of the third ventricle)/brain abnormality and absence of the septum pellucidum. It is unknown if an autopsy was performed. The action taken with mRNA-1273 (COVID 19 Vaccine Moderna) (Transplacental) was unknown. For mRNA-1273 (COVID 19 Vaccine Moderna) (Transplacental), the reporter did not provide any causality assessments. No concomitant and treatment medications were provided. Patient died because of brain abnormality on 31/21/2021. Gestational period at exposure was 3 weeks 3 days. Company comment: This is a spontaneous case concerning a foetus patient of unknown gender with relevant maternal medical history of maternal exposure to mRNA-1273 vaccine during pregnancy at 3 weeks 3 days age of gestation, who experienced the unexpected, serious event of congenital brain damage (agenesis of the corpus callosum, asymmetrical and lack of brain structures, absence of the septum pellucidum, and fusion of the thalami (atresia of the third ventricle)). The event congenital brain damage (agenesis of the corpus callosum, asymmetrical and lack of brain structures, absence of the septum pellucidum, and fusion of the thalami (atresia of the third ventricle)) exact occurrence unknown but confirmed approximately by the end of the fifth month of pregnancy. Diagnostic and laboratories procedures were done with remarkable results of serodiagnosis for rubella specific IgG: 76 IU/mL positive, AFP: 162.6 ng/mL, serodiagnosis for toxoplasmosis specific IgG: 137 IU/mL positive, fasting glycemia 0.98 g/L. No reported treatment information. The outcome of the event congenital brain damage (agenesis of the corpus callosum, asymmetrical and lack of brain structures, absence of the septum pellucidum, and fusion of the thalami (atresia of the third ventricle)) was fatal. The remarkable results of serodiagnosis for rubella specific IgG: 76 IU/mL positive, AFP: 162.6 ng/mL, serodiagnosis for toxoplasmosis specific IgG: 137 IU/mL positive remain confounders. The benefit-risk relationship of mRNA-1273 vaccine is not affected by this report. This case was linked to MOD-2022-454735 (Parent-Child Link). See case MOD-2022-454735 for details regarding the child case. Most recent FOLLOW-UP information incorporated above includes: On 21-Jan-2022: Follow up received on 21-JAN-2021 included: correspondence contact, New events, parent's lab data added, country updated. On 21-Jan-2022: Translation received on 22-Jan-2022, includes significant information updated.; Sender's Comments: This is a spontaneous case concerning a foetus patient of unknown gender with relevant maternal history of maternal exposure to mRNA-1273 vaccine during pregnancy at 3 weeks 3 days age of gestation, who experienced the unexpected, serious event of congenital brain damage (agenesis of the corpus callosum, asymmetrical and lack of brain structures, absence of the septum pellucidum, and fusion of the thalami (atresia of the third ventricle)). The event congenital brain damage (agenesis of the corpus callosum, asymmetrical and lack of brain structures, absence of the septum pellucidum, and fusion of the thalami (atresia of the third ventricle)) exact occurrence unknown but confirmed approximately by the end of the fifth month of pregnancy. Diagnostic and laboratories procedures were done with remarkable results of serodiagnosis for rubella specific IgG: 76 IU/mL positive, AFP: 162.6 ng/mL, serodiagnosis for toxoplasmosis specific IgG: 137 IU/mL positive, fasting glycemia 0.98 g/L. No reported treatment information. The outcome of the event congenital brain damage (agenesis of the corpus callosum, asymmetrical and lack of brain structures, absence of the septum pellucidum, and fusion of the thalami (atresia of the third ventricle)) was fatal. The remarkable results of serodiagnosis for rubella specific IgG: 76 IU/mL positive, AFP: 162.6 ng/mL, serodiagnosis for toxoplasmosis specific IgG: 137 IU/mL positive remain confounders. The benefit-risk relationship of mRNA-1273 vaccine is not affected by this report.; Reported Cause(s) of Death: agenesis of the corpus callosum, asymmetrical and lack of brain structures; Fusion of thalami (atresia of the third ventricle)/brain abnormality; absence of the septum pellucidum

CASE 7 (VAERS 2106393) – A 39 year old woman had 2nd Pfizer dose on Jul. 28, 2021 and became pregnant 2 months later in Oct. 2021. At 1st ultrasound, fetus had congenital heart malformation and she needed a medical termination of pregnancy in Dec. 2021.

VAERS ID: 2106393 **Vaccinated:** 2021-07-28
VAERS Form: 2 **Onset:** 0000-00-00
Age: **Submitted:** 0000-00-00
Sex: Unknown **Entered:** 2022-02-12
Location: Foreign

Vaccination / Manufacturer (1 vaccine)	Lot / Dose	Site / Route
COVID19: COVID19 (COVID19 (PFIZER-BIONTECH)) PFIZER BIONTECH	UNKNOWN 2	- / OT

Administered by: Other **Purchased by:** ??

Symptoms: Heart disease congenital, Ultrasound scan, Maternal exposure before pregnancy

Life Threatening? No

Birth Defect? Yes

Died? Yes

Date died: 2021-12-01

Permanent Disability? No

Recovered? No

Office Visit (V2.0)? No

ER or Office Visit (V1.0)? No

ER or ED Visit (V2.0)? No

Hospitalized? No

Previous Vaccinations:

Other Medications:

Current Illness:

Preexisting Conditions:

Allergies:

Diagnostic Lab Data: Test Name: ultrasound; Result Unstructured Data: Test Result: heart malformation was detected

CDC 'Split Type': FRPFIZER INC202200216482

Write-up: Maternal exposure before pregnancy; Heart malformation; This is a spontaneous report received from a contactable reporter(s) (Consumer) from a regulatory authority. The reporter is the parent. Regulatory number: FR-AFSSAPS-NC20220555. A fetus patient was exposed to bnt162b2 (COMIRNATY), transplacental, administration date 28Jul2021 (Lot number: Unknown) as dose 2, single for covid-19 immunisation. The mother of the patient was 39 year-old. Date of last menstrual period of the mother: Oct2021. The mother's relevant medical history and concomitant medications were not reported. The mother's vaccination history included: Comirnaty (dose 1), for covid-19 immunisation. The following information was reported: MATERNAL EXPOSURE BEFORE PREGNANCY (death, congenital anomaly), outcome "fatal", described as "Maternal exposure before pregnancy"; HEART DISEASE CONGENITAL (death, congenital anomaly), outcome "fatal", described as "Heart malformation". Onset date of pregnancy 2 months after vaccination, around October. Following the 2nd vaccine dose, pfizer, very severe pain in the lower abdomen for 2 months, disrupted cycles, then she became pregnant when the pain subsided. At the first ultrasound, a heart malformation was detected. She had to have a medical termination of pregnancy. She was vaccinated Moderna, 3rd dose, at the end of December after my medical termination of pregnancy, she still didn't have my period. Death due to the effect in December 2021. The pregnancy resulted in elective termination. The patient underwent the following laboratory tests and procedures: ultrasound scan: heart malformation was detected. The patient date of death was Dec2021. The reported cause of death was heart disease congenital. It was not reported if an autopsy was performed. No follow-up attempts are possible; information about lot/batch number cannot be obtained. No further information is expected.; Sender's Comments: Linked Report(s) : PFIZER INC-202101607031 Maternal case; Reported Cause(s) of Death: Heart malformation

CASE 8 (VAERS 2195334) – A pregnant woman had Pfizer jabs at 3wk4d and 6wk5d, and had medical termination of pregnancy at 26wk as fetus had congenital heart anomaly – congenital tricuspid valve atresia, ventricular septal defect, brachydactyly.

VAERS ID: 2195334 **Vaccinated:** 2021-08-24
VAERS Form: 2 **Onset:** 2021-08-02
Age: **Submitted:** 0000-00-00
Sex: Male **Entered:** 2022-03-24
Location: Foreign

Vaccination / Manufacturer (1 vaccine)	Lot / Dose	Site / Route
COVID19: COVID19 (COVID19 (PFIZER-BIONTECH)) / PFIZER/BIONTECH	FG9428 / 2	- / OT

Administered by: Other **Purchased by:** ??

Symptoms: Ultrasound antenatal screen, Ultrasound scan, Ventricular septal defect, Congenital tricuspid valve atresia, Cytogenetic analysis, Investigation, Human chorionic gonadotropin, Maternal exposure during pregnancy, Brachydactyly

Life Threatening? No

Birth Defect? Yes

Died? Yes

Date died: 2022-01-06

Permanent Disability? No

CDC 'Split Type': FRPFIZER INC202200435524

Write-up: no 5th finger brachymesophalangy; Congenital ventricular septal defect; Congenital tricuspid valve atresia; COMIRNATY vaccine at 3 weeks of amenorrhea + 4 days and at 6 weeks of amenorrhea + 5 days: This is a spontaneous report received from a contactable reporter(s) (Physician) from the Regulatory Authority. Regulatory number: FR-AFSSAPS-AN20220710. A fetus male patient was exposed to bnt162b2 (COMIRNATY), transplacental, administration date 24Aug2021 (Lot number: FG9428) as dose 2, single and transplacental, administration date 02Aug2021 (Lot number: FE2707) as dose 1, single for covid-19 immunisation. The mother's relevant medical history included: "blood group O" (unspecified if ongoing); "Rh positive" (unspecified if ongoing); "smoking: no" (unspecified if ongoing); "parity 1" (unspecified if ongoing), notes: Previous pregnancies: Gestation 2. Parity 1, live birth on 2020. Gestational age 41 week of amenorrhea + 0 day. Birth weight 3650g. Date of last menstrual period of the mother: 08Jul2021. The mother was 1 trimester pregnant at the time of exposure to bnt162b2. The mother was 3 weeks pregnant at the event onset. The mother is expected to deliver one baby(s). The mother's concomitant medications were not reported. The following information was reported: MATERNAL EXPOSURE DURING PREGNANCY (death) outcome "fatal", described as "COMIRNATY vaccine at 3 weeks of amenorrhea + 4 days and at 6 weeks of amenorrhea + 5 days" VENTRICULAR SEPTAL DEFECT death, congenital anomaly, outcome "fatal", described as "Congenital ventricular septal defect"; CONGENITAL TRICUSPID VALVE ATRESIA (death, congenital anomaly), outcome "fatal", described as "Congenital tricuspid valve atresia"; BRACHYDACTYLY (congenital anomaly, medically significant), outcome "unknown", described as "no 5th finger brachymesophalangy". The baby weighed 950 grams. The pregnancy resulted in elective termination. The fetal outcome is congenital anomaly. The patient underwent the following laboratory tests and procedures: cytogenetic analysis: snp array by amniocentesis: no

CASE 9 (VAERS 2195640) - Pregnant woman had Pfizer vaccines at 2wk (Aug. 11, 2021) and 4mo (Dec. 01, 2021) of pregnancy. Elective medical termination of pregnancy 16 days after 2nd Pfizer dose due to congenital CNS anomaly - corpus callosum agenesis.

VAERS ID: 2195640 **Vaccinated:** 2021-12-01
VAERS Form: 2 **Onset:** 2021-12-17
Age: **Submitted:** 0000-00-00
Sex: Unknown **Entered:** 2022-03-24
Location: Foreign

Vaccination / Manufacturer (1 vaccine)	Lot / Dose	Site / Route
COVID19: COVID19 (COVID19 (PFIZER-BIONTECH)) / PFIZER/BIONTECH	- / 2	- / OT

Administered by: Other **Purchased by:** 22

Symptoms: Congenital central nervous system anomaly, Ultrasound scan, Maternal exposure during pregnancy

Life Threatening? No

Birth Defect? Yes

Died? Yes

Date died: 0000-00-00

Permanent Disability? No

Recovered? No

Office Visit (V2.0)? No

ER or Office Visit (V1.0)? No

ER or ED Visit (V2.0)? No

Hospitalized? No

Previous Vaccinations:

Other Medications:

Current Illness:

Preexisting Conditions:

Allergies:

Diagnostic Lab Data: Test Date: 20211217; Test Name: structural ultrasound examination; Result Unstructured Data: Test Result: Corpus callosum agenesis

CDC 'Split Type': NLPFIZER INC202200399112

Write-up: Vaccination during pregnancy; In fetus of patient: corpus callosum agenesis. This is a spontaneous report received from a contactable reporter(s) (Physician) from the Regulatory Authority-WEB. Regulatory number: NL-LRB-00796529. A fetus patient was exposed to bnt162b2 (COMIRNATY), transplacental, administration date 01Dec2021 (Batch/Lot number: unknown) as dose 2, single and transplacental, administration date 11Aug2021 (Batch/Lot number: unknown) as dose 1, single for covid-19 immunisation. The mother's relevant medical history included: "Maternal vaccine exposure", start date: 01Aug2021, stop date: 01Aug2021. The mother is expected to deliver one baby(s). The mother's concomitant medications were not reported. The following information was reported: CONGENITAL CENTRAL NERVOUS SYSTEM ANOMALY (death, congenital anomaly, medically significant) with onset 17Dec2021, outcome "fatal", described as "In fetus of patient: corpus callosum agenesis"; MATERNAL EXPOSURE DURING PREGNANCY (death, congenital anomaly, medically significant), outcome "fatal", described as "Vaccination during pregnancy". The pregnancy resulted in elective termination. The patient underwent the following laboratory tests and procedures: ultrasound scan: (17Dec2021) corpus callosum agenesis. The patient date of death was unknown. The reported cause of death was congenital central nervous system anomaly. Clinical Information: This serious spontaneous report from a physician concerns a foetus, unknown sex, who was diagnosed with corpus callosum agenesis (congenital anomaly), during the ultrasound at a pregnancy duration of 20 weeks. The mother was vaccinated at a pregnancy duration of about 2 weeks and at a pregnancy duration of about 4 months. The pregnancy was terminated. Vaccines: 11Aug2021 and 01Dec2021 (both Pfizer). Diagnosis is ultrasound made after referral from 20 weeks structural ultrasound examination. Outcome of pregnancy: termination of pregnancy. BSN available: yes. Mother had no Previous COVID-19 infection. No follow-up attempts are possible; information about lot/batch number cannot be obtained. No further information is expected.; Sender's Comments: Linked Report(s) : NL-PFIZER INC-202200405353 Mother/child case; Reported Cause(s) of Death: Corpus callosum agenesis

CASE 10 (VAERS 2272573) - Pregnant woman had 1st Moderna dose on April 16, 2021, 7 months later fetus was diagnosed with congenital CNS anomaly - corpus callosum agenesis, and stillbirth on Nov. 2, 2021.

CASE 11 (VAERS 2259562) - Pregnant woman had 1st dose of Pfizer on Mar. 7, 2021 at 14wk of pregnancy and 2nd dose on Mar. 28, 2021. Fetus died in Jan. 2022 due to congenital defects - exomphalos (omphalocele with liver and intestines) and tricuspid regurgitation.

VAERS ID: 2259562 **Vaccinated:** 2021-03-28
VAERS Form: 2 **Onset:** 2022-01-07
Age: **Submitted:** 0000-00-00
Sex: Unknown **Entered:** 2022-04-30
Location: Foreign

Vaccination / Manufacturer (1 vaccine)	Lot / Dose	Site / Route
COVID19: COVID19 (COVID19 (PFIZER-BIONTECH)) / PFIZER/BIONTECH	ET7205 / 2	- / OT

Administered by: Other **Purchased by:** ??

Symptoms: Exomphalos, Tricuspid valve incompetence, Foetal death, Maternal exposure during pregnancy

Life Threatening? No

Birth Defect? Yes

Died? Yes

Date died: 0000-00-00

Permanent Disability? No

Recovered? No

Office Visit (V2.0)? No

ER or Office Visit (V1.0)? No

ER or ED Visit (V2.0)? No

Hospitalized? No

Previous Vaccinations:

Other Medications:

Current Illness:

Preexisting Conditions:

Allergies:

Diagnostic Lab Data:

CDC 'Split Type': ROPFIZER INC202200618489

Write-up: Maternal Exposure During Pregnancy; death; severe omphalocele; Tricuspid regurgitation; This is a spontaneous report received from contactable reporter(s) (Physician) from the RA-WEB. Regulatory number: RO-NMA-2022-SPCOV16267. A 14-week-old patient received BNT162b2 (COMIRNATY), on 07Mar2021 as dose 1, 30 ug single (Lot number: EP2166) and on 28Mar2021 as dose 2, 30 ug single (Lot number: ET7205), all intramuscular for covid-19 immunisation. The patient's relevant medical history was not reported. There were no concomitant medications. The mother's past drug history included: Comirnaty, start date: 07Mar2021, stop date: 07Mar2021, for COVID-19 immunisation; Comirnaty, start date: 28Mar2021, stop date: 28Mar2021, for COVID-19 immunisation. The following information was reported: TRICUSPID VALVE INCOMPETENCE (death, congenital anomaly, medically significant) with onset 07Jan2022, outcome "fatal", described as "Tricuspid regurgitation"; EXOMPHALOS (death, congenital anomaly, medically significant) with onset 07Jan2022, outcome "fatal", described as "severe omphalocele"; FOETAL DEATH (death, medically significant) with onset 17Jan2022, outcome "fatal", described as "death"; MATERNAL EXPOSURE DURING PREGNANCY (death, medically significant), outcome "fatal". The patient date of death was unknown. Reported cause of death: "Foetal death". Additional information: 2 pregnancies with normal evolution, brought to term and normal evolution of the two children; pregnant for the 3rd time with a 13 w old evolutive pregnancy, estimated date of birth. With the occasion of the morphology ultrasound, at 13w, the patient was announced that the fetus presented a severe omphalocele, a tricuspid regurgitation and a possible aneuploid anomaly. On 13-Jan-2022, the patient underwent for a second opinion ultrasound investigation, that confirmed the major abdominal wall defect (omphalocele that included the liver and the intestinal). No follow-up attempts are possible. No further information is expected.; Reported Cause(s) of Death: Fetal death

My Take...

Pregnant women who were exposed to Pfizer or Moderna COVID-19 mRNA vaccines in the first trimester, were at risk of their fetus developing congenital malformations:

- of the brain (missing or abnormal structures, agenesis, atresia, etc)
- of the heart (abnormal structures – valve atresia or insufficiency, transposition of vessels, univentricle, ventricular septal defect, aorta hypoplasia, etc)
- of the abdominal wall (exomphalos)
- of the limbs (hypoplasia, bony agenesis, missing fingers, radial zamba hand, etc)

Not “safe in pregnancy” by any measure.

The reality is that women were lied to by their family doctors and by their obstetricians/gynecologists and were not informed about the risks of congenital malformations that could be caused by Pfizer or Moderna COVID-19 mRNA vaccines.

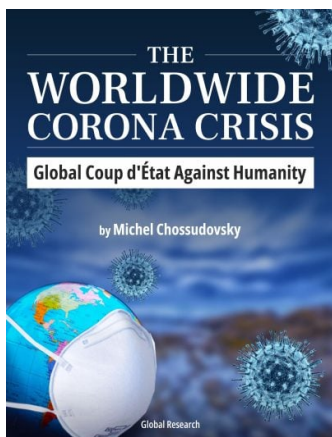
*

Note to readers: Please click the share button above. Follow us on Instagram and Twitter

and subscribe to our Telegram Channel. Feel free to repost and share widely Global Research articles.

Dr. William Makis is a Canadian physician with expertise in Radiology, Oncology and Immunology. Governor General's Medal, University of Toronto Scholar. Author of 100+ peer-reviewed medical publications.

Featured image is from NaturalNews.com



The Worldwide Corona Crisis, Global Coup d'Etat Against Humanity

by Michel Chossudovsky

Michel Chossudovsky reviews in detail how this insidious project “destroys people’s lives”. He provides a comprehensive analysis of everything you need to know about the “pandemic” — from the medical dimensions to the economic and social repercussions, political underpinnings, and mental and psychological impacts.

“My objective as an author is to inform people worldwide and refute the official narrative which has been used as a justification to destabilize the economic and social fabric of entire countries, followed by the imposition of the “deadly” COVID-19 “vaccine”. This crisis affects humanity in its entirety: almost 8 billion people. We stand in solidarity with our fellow human beings and our children worldwide. Truth is a powerful instrument.”

ISBN: 978-0-9879389-3-0, Year: 2022, PDF Ebook, Pages: 164, 15 Chapters

We encourage you to support the eBook project by making a donation through Global Research’s [DonorBox “Worldwide Corona Crisis” Campaign Page](#).

The original source of this article is [COVID Intel](#)
Copyright © [Dr. William Makis](#), [COVID Intel](#), 2023

[Comment on Global Research Articles on our Facebook page](#)

[Become a Member of Global Research](#)

Disclaimer: The contents of this article are of sole responsibility of the author(s). The Centre for Research on Globalization will not be responsible for any inaccurate or incorrect statement in this article. The Centre of Research on Globalization grants permission to cross-post Global Research articles on community internet sites as long the source and copyright are acknowledged together with a hyperlink to the original Global Research article. For publication of Global Research articles in print or other forms including commercial internet sites, contact: publications@globalresearch.ca

www.globalresearch.ca contains copyrighted material the use of which has not always been specifically authorized by the copyright owner. We are making such material available to our readers under the provisions of "fair use" in an effort to advance a better understanding of political, economic and social issues. The material on this site is distributed without profit to those who have expressed a prior interest in receiving it for research and educational purposes. If you wish to use copyrighted material for purposes other than "fair use" you must request permission from the copyright owner.

For media inquiries: publications@globalresearch.ca