

Bullous Pemphigoid and Pemphigus Vulgaris: Severe Skin Injuries Caused by Pfizer and Moderna COVID-19 mRNA Vaccines

22 published photographed cases (Viewer discretion is advised)

By [Dr. William Makis](#)

Theme: [Science and Medicine](#)

Global Research, November 17, 2023

[COVID Intel](#)

All Global Research articles can be read in 51 languages by activating the Translate Website button below the author's name.

To receive Global Research's Daily Newsletter (selected articles), [click here](#).

Click the share button above to email/forward this article to your friends and colleagues. Follow us on [Instagram](#) and [Twitter](#) and subscribe to our [Telegram Channel](#). Feel free to repost and share widely Global Research articles.

[2023 Feb \(Hsuan-Chi Chen et al\)](#) - Pemphigus aggravation following Pfizer-BioNTech vaccination: A case report and review of literature

- 39M had 1st dose of Pfizer mRNA
- one week later he developed painful vesicles and erosions that progressed rapidly over his trunk and limbs, involving 30% of total body surface area.
- oral mucosal erosions also observed
- Diagnosis: Pemphigus Vulgaris, treated in a burn unit with methylprednisolone and rituximab, then azathioprine

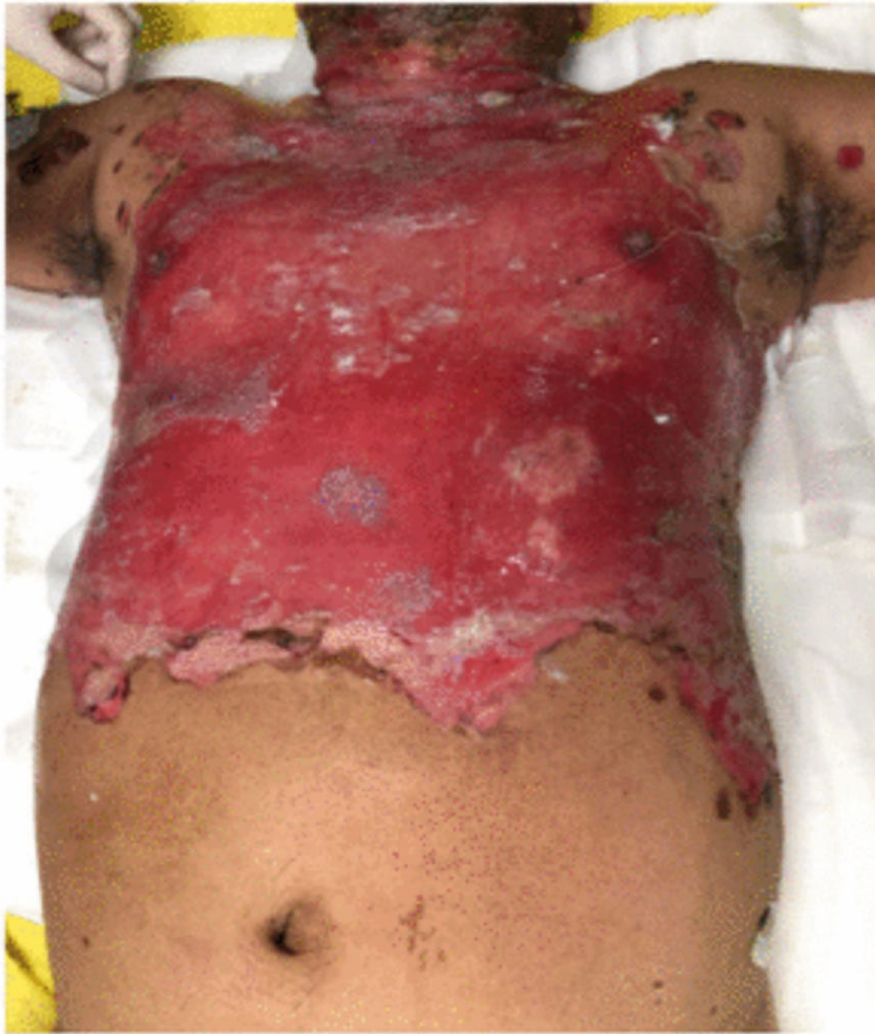
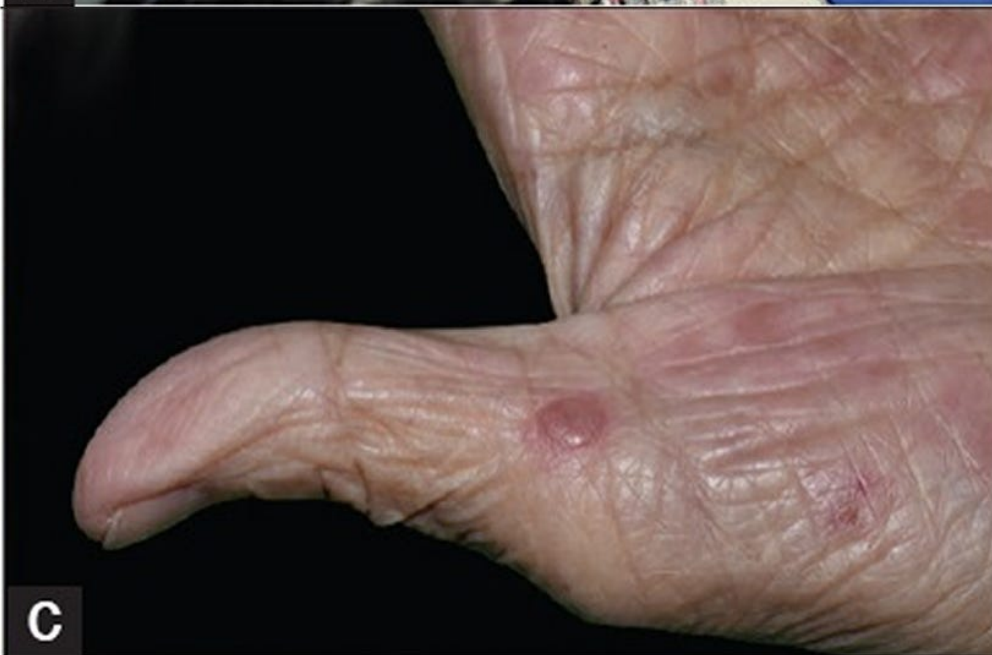
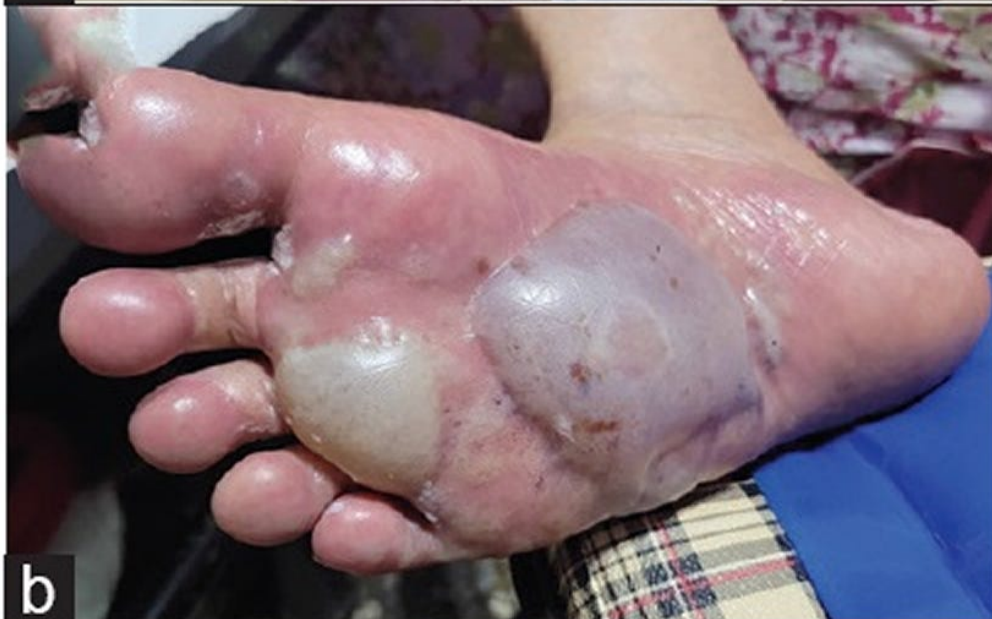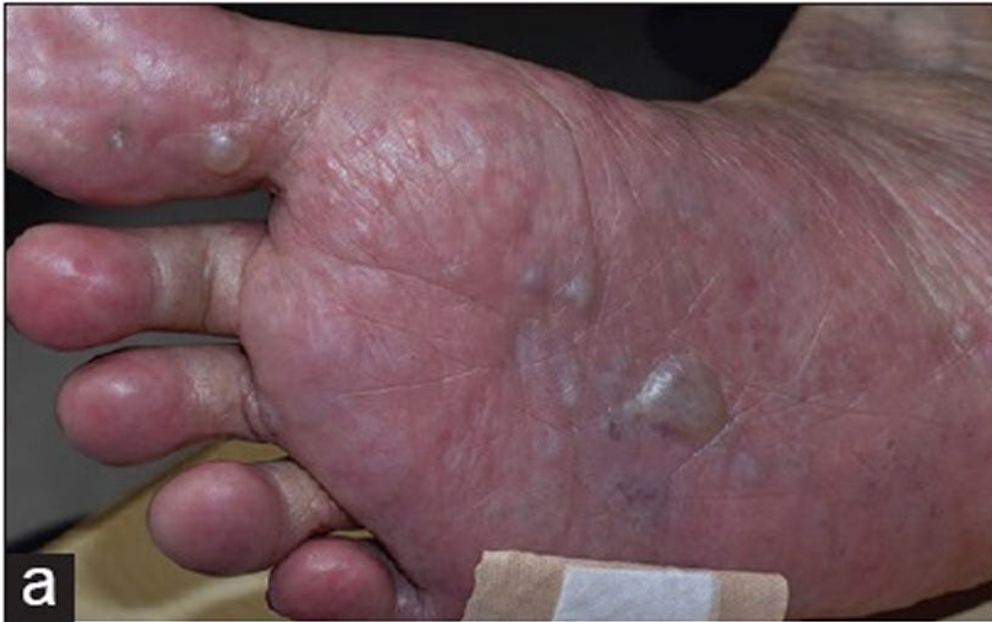FIGURE 1 Diffuse coalescing erosions and scattered flaccid blisters developed after Pfizer-BioNTech COVID-19 vaccine (2 wks after admission).

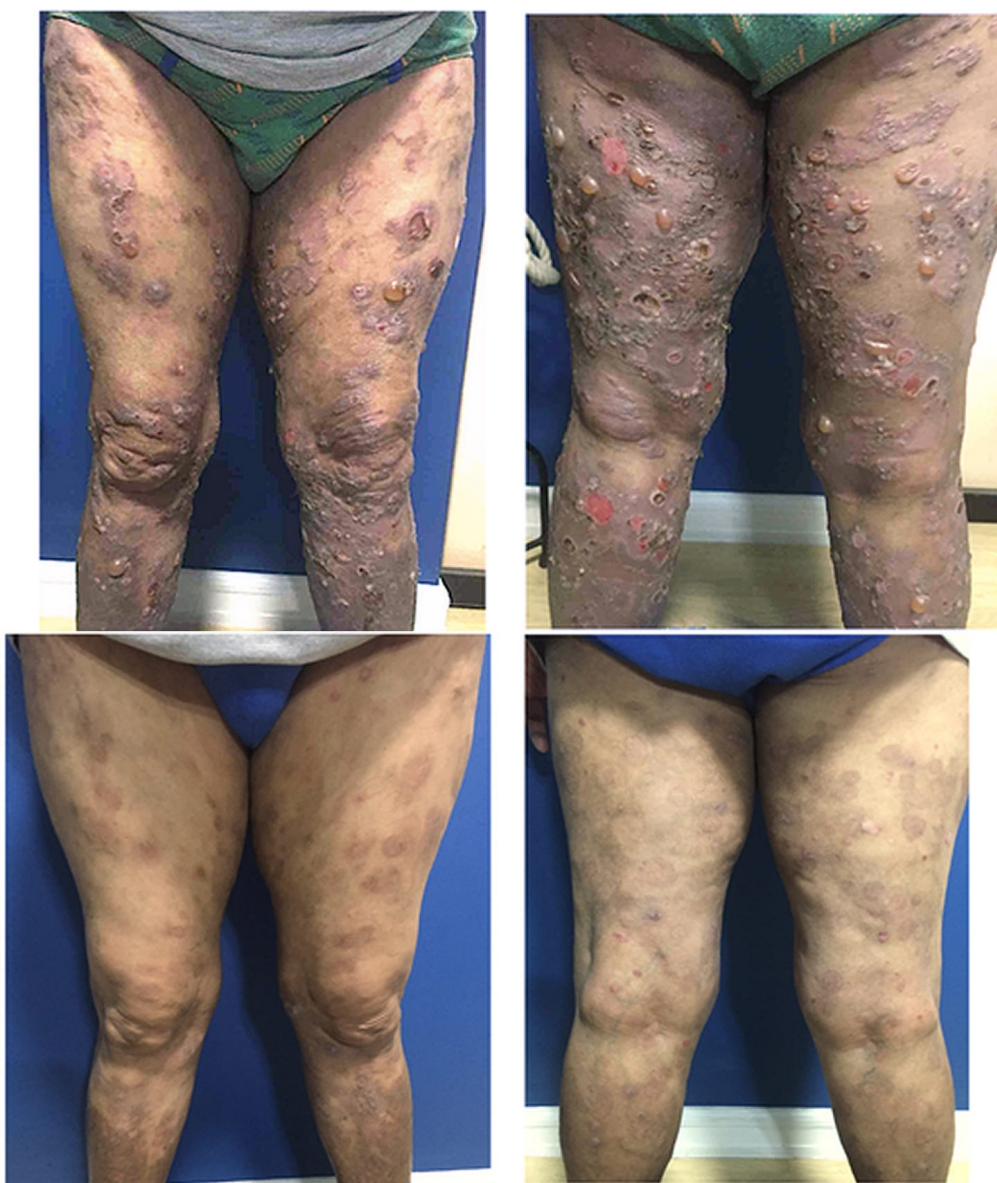
[2023 Jan \(Hsieh et al\)](#) - Dyshidrotic bullous pemphigoid developing after Moderna mRNA-1273 vaccination

- 94F had 2nd Moderna mRNA dose
- 18 days later she developed large bullae on the soles of her feet.
- Also had itchy rashes on her trunk.
- The bullae then rapidly enlarged
- Diagnosis: dyshidrotic bullous pemphigoid, treated with oral steroids



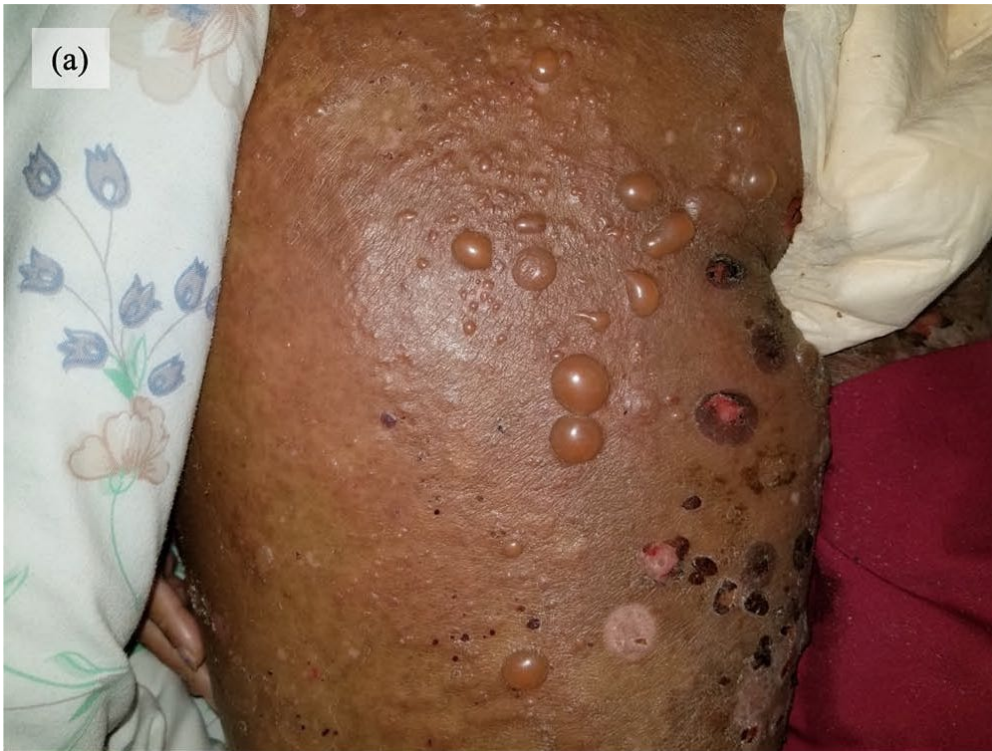[2022 Dec \(Merilleno et al\)](#) - Bullous pemphigoid in a patient with psoriasis after mRNA COVID-19 vaccination

- 62M Filipino man had a history of stable long standing psoriasis vulgaris
- he had two doses of AstraZeneca COVID-19 vaccine a year ago with no reactions
- He then had a 1st Pfizer mRNA booster
- 2 days later he developed multiple pruritic tense vesicles and bullae, with erosions and serous crusting on the lower extremities
- Diagnosis: bullous pemphigoid
- Treatment: prednisone, tetracycline, diphenhydramine, methotrexate
- Images show treatment response after 3 months, the patient had no new lesions and showed post-inflammatory hyperpigmentation

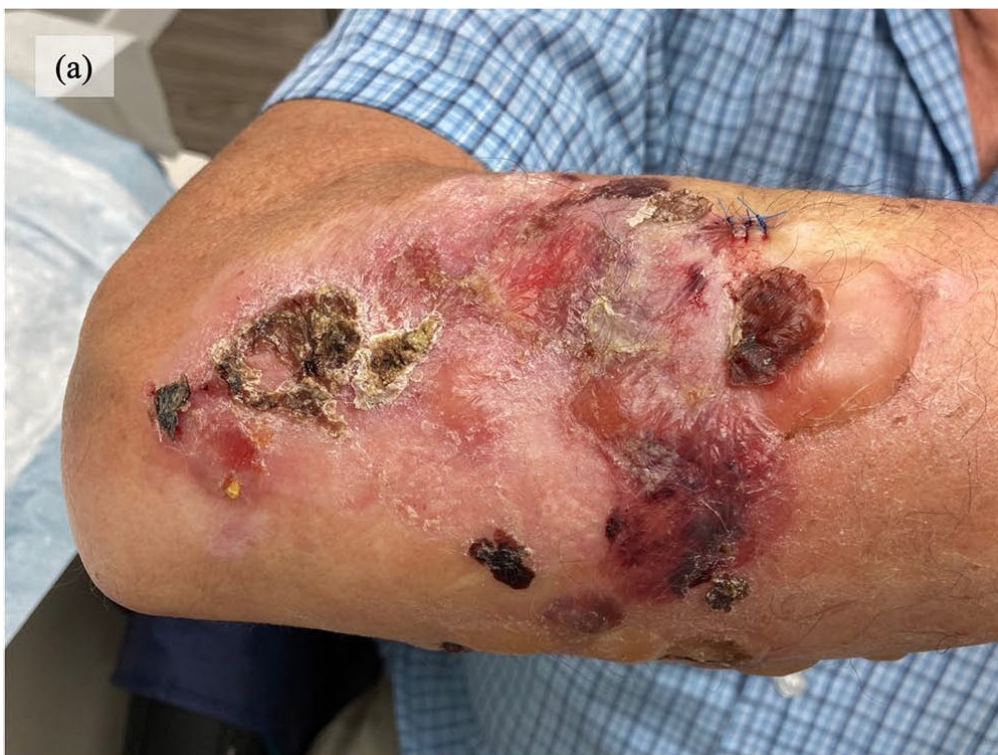

[Wan et al](#) – Association between COVID-19 vaccination and bullous pemphigoid – a case series and literature review [2022 Oct \(Vincent\)](#)

- CASE 1 – 50F had 3 month history of pruritic rash that began after 2nd dose of Pfizer mRNA
- P/E: pink plaques with both non-hemorrhagic and hemorrhagic bullae scattered on the extremities, neck, chin, and torso
- Diagnosis: bullous pemphigoid
- Treatment: short Prednisone taper plus methotrexate

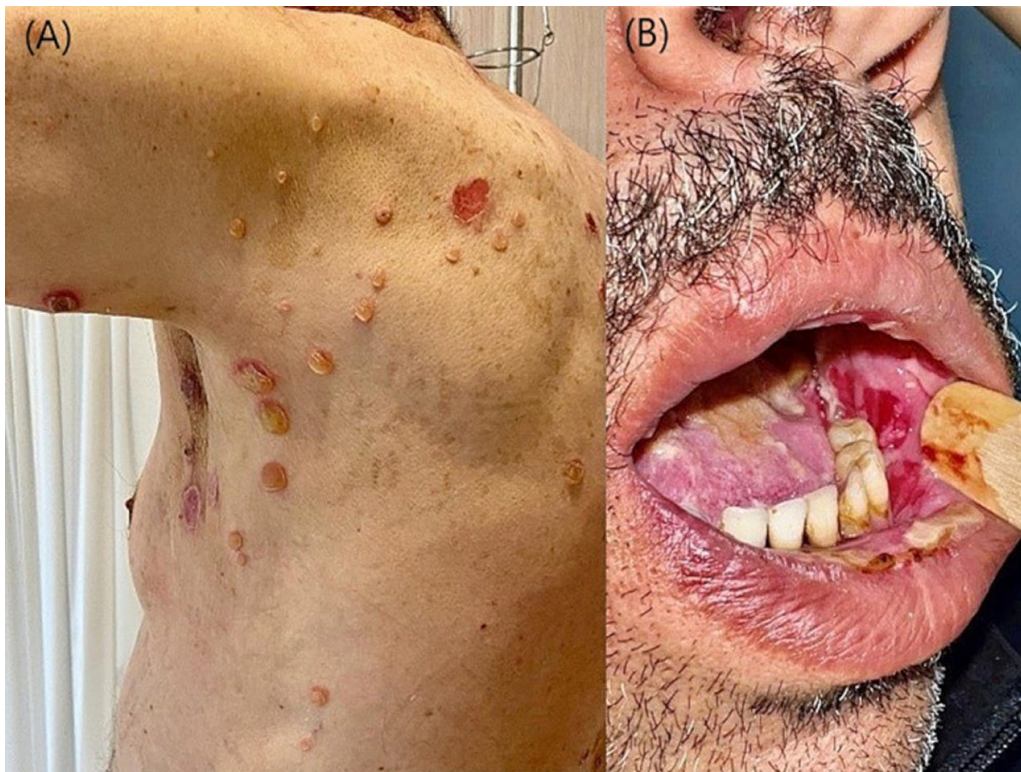

- CASE 2 – 82M presented with 2 month history of pruritic rash on his forearm and legs that started 3 days after 2nd Pfizer mRNA
- P/E: non-hemorrhagic and hemorrhagic bullae were observed on the right forearm with smaller vesicles noted on his calves.
- Diagnosis: bullous pemphigoid
- Treatment: clobetasol propionate 0.05% ointment
- He took a third COVID-19 Moderna vaccine after his lesions resolved (!)



[2022 Sep \(Agharbi et al\)](#) – Pemphigus vulgaris following second dose of mRNA-(Pfizer-BioNTech) COVID-19 vaccine

- 72M had 2nd dose of Pfizer mRNA
- 1 week later he developed a blistering eruption starting in oral mucosa, and spread 2 weeks later to head, neck, trunk and all extremities.
- P/E: post-bullous erosions as well as intact flaccid blisters and mucosal erosions
- Diagnosis: Pemphigus Vulgaris, treated with prednisone and azathioprine



[2022 Aug \(Bryan Daines et al\)](#) – A new eruption of bullous pemphigoid following mRNA COVID-19 vaccination

- Bullous pemphigoid (BP) is an uncommon autoimmune blistering disease which characteristically affects elderly adults with an incidence of 150–330 cases per million people per year in individuals over 80 years of age.
- The pathogenesis of BP involves autoantibodies directed against antigens in the hemidesmosome, causing a subepidermal split and subsequent bullae formation.
- Rare cases of BP have been reported following a variety of vaccinations including those for diphtheria, tetanus, pertussis, polio, influenza, Haemophilus influenzae type B, hepatitis B, bacillus Calmette-Guérin, pneumococcus, and herpes zoster, though true association is unclear
- 70M had 2nd dose of Pfizer mRNA
- next day he had an intensely pruritic eruption of pink plaques
- P/E: brightly erythematous, indurated plaques were present on the trunk, arms, and legs with intact and denuded bullae on the bilateral palms
- Diagnosis: bullous pemphigoid

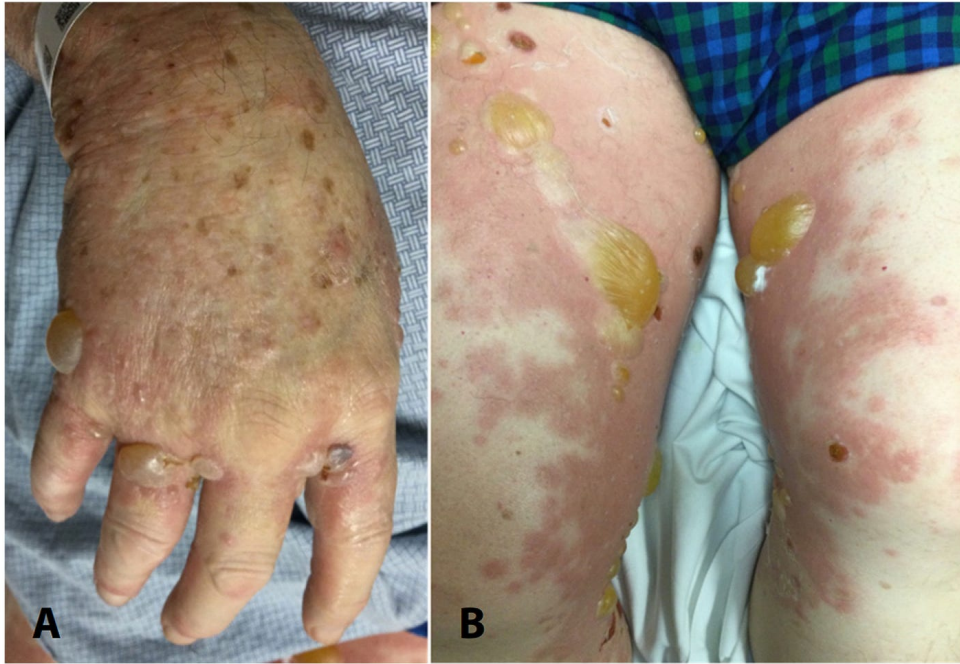
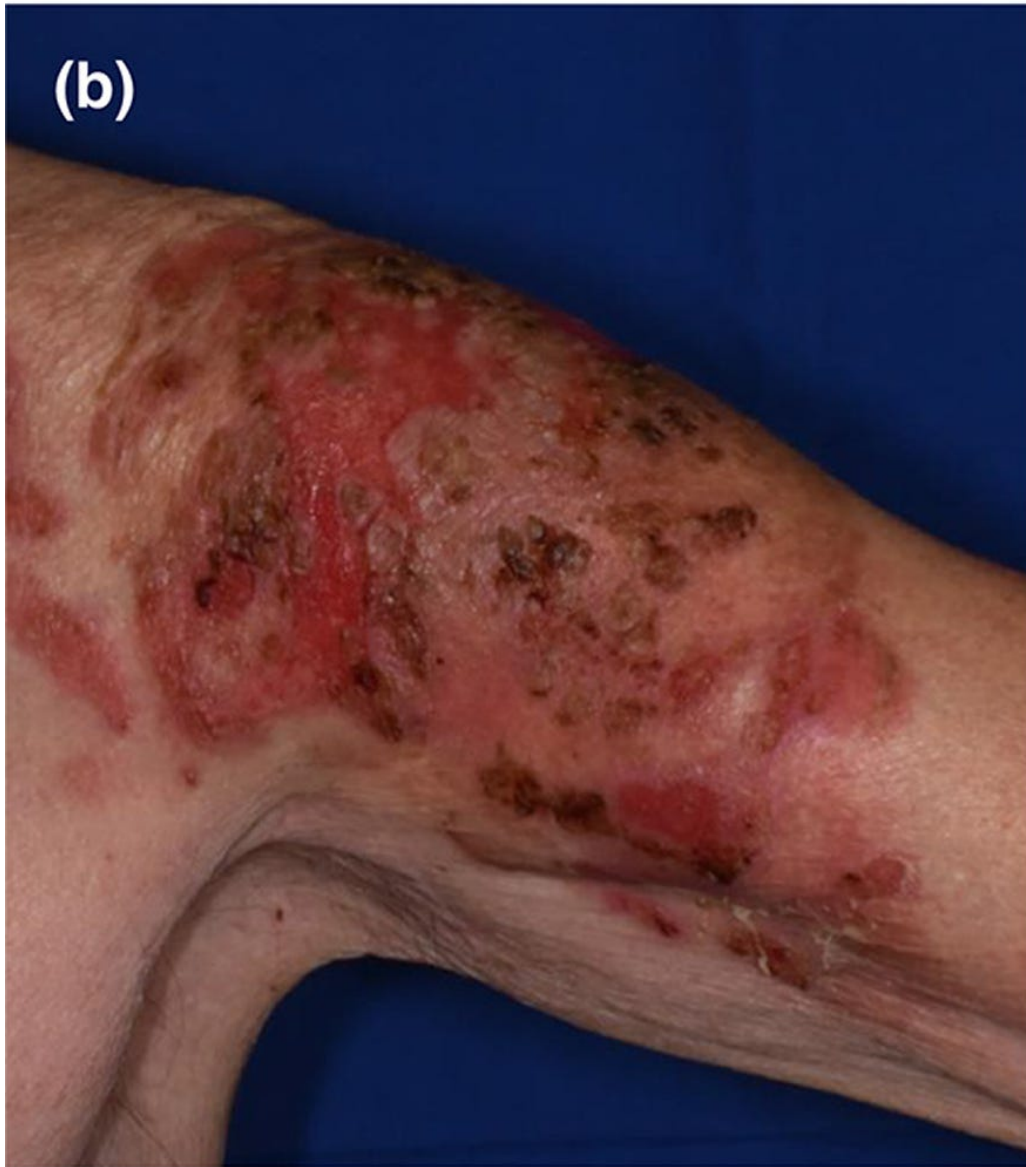

Figure 1. *Bullous pemphigoid eruption with erythematous, indurated plaques with intact and denuded bullae*

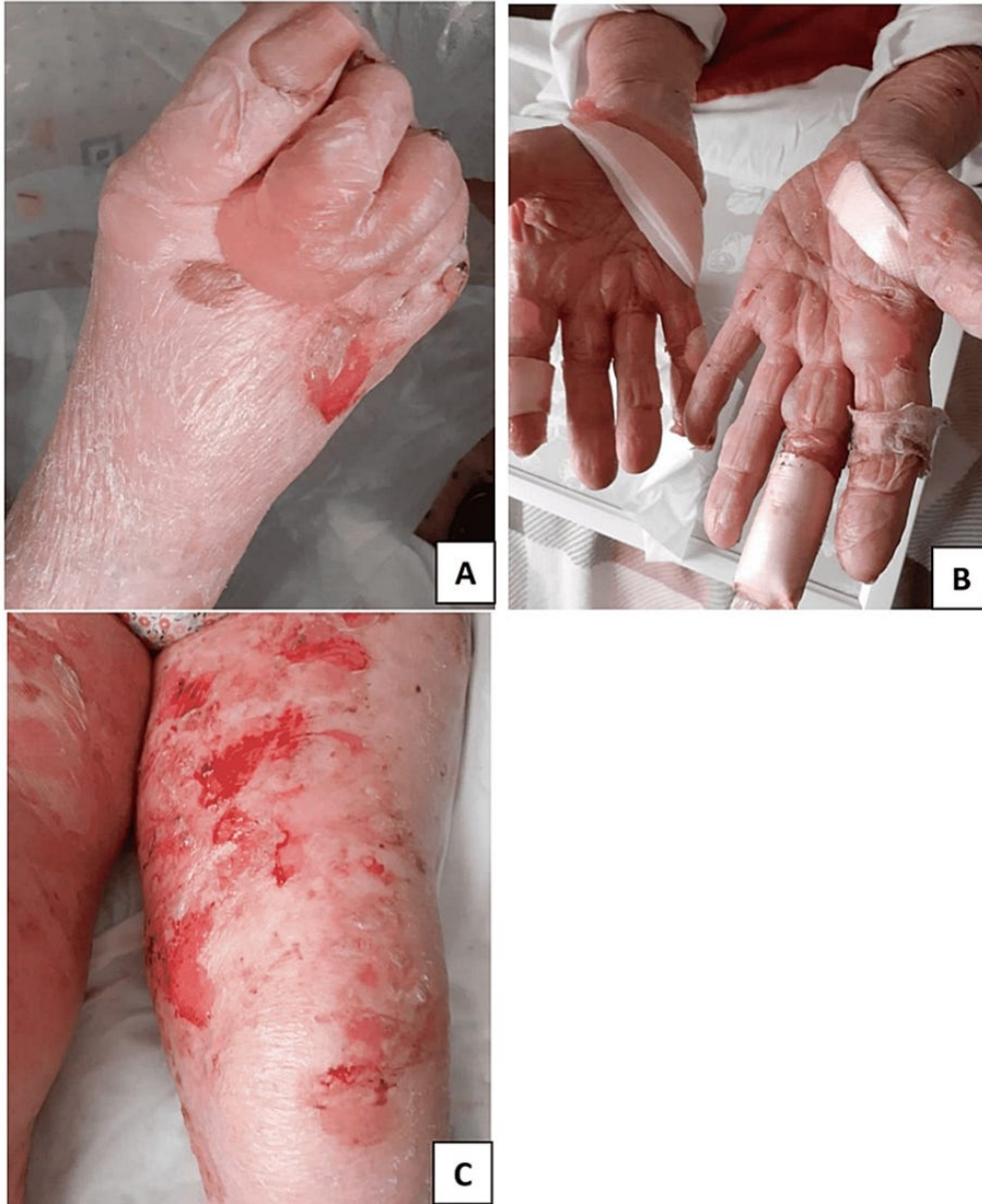[2022 July \(Norimatsu et al\)](#) – Pemphigus vulgaris with advanced hypopharyngeal and gastric cancer following SARS-CoV-2 vaccination

- 86M Japanese Man had 2nd Pfizer mRNA
- next day flaccid bullae appeared mainly in the lumbar region and presented to hospital 11 days later
- P/E: flaccid bullae scattered mainly in the right lumbar region and left upper arm.
- Diagnosis: Pemphigus Vulgaris



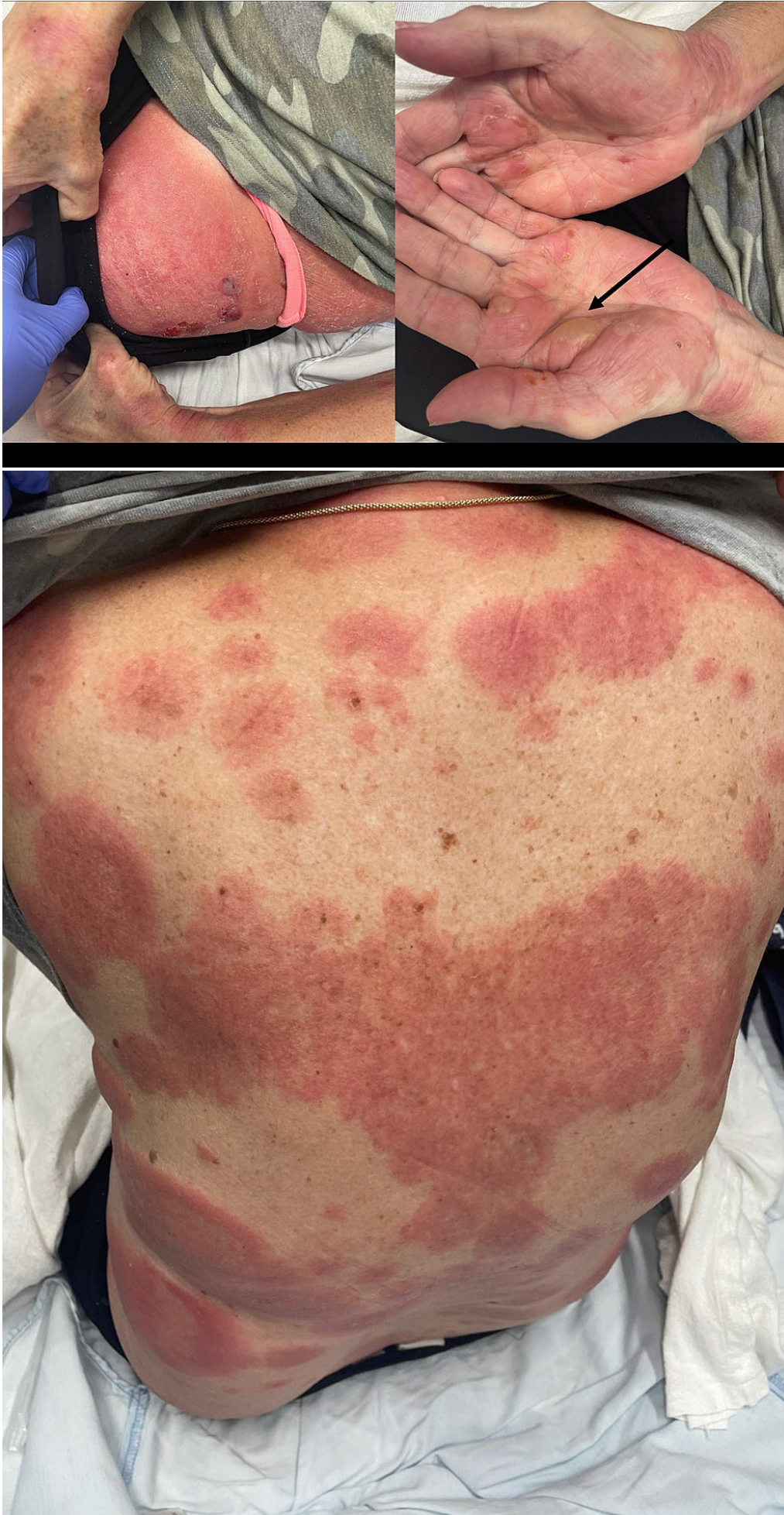[2022 Jun \(Shanshal\)](#) - Dyshidrosiform Bullous Pemphigoid Triggered by COVID-19 Vaccination

- 90F had 1st Pfizer mRNA Vaccine on Dec.29, 2020
- she had a skin eruption 1 week later.
- after 2nd Pfizer mRNA dose on Mar.18, 2021, the rash worsened considerably with severe itching
- P/E: widespread eczematous rash and excoriation marks involving the trunk and extremities.
- On May 16, 2021 she was re-admitted with severe itchy and painful large intact blisters involving the palms and soles
- Diagnosis: bullous pemphigoid
- caused by acquired autoimmune IgG against two hemidesmosomal antigens (BpAg 180 and 230) in patients with underlying genetic predisposition.
- Dyshidrosiform pemphigoid is a rare clinical variant of bullous pemphigoid where itchy blisters primarily involve the palms and soles and may mimic a vesicular eczema flare-up



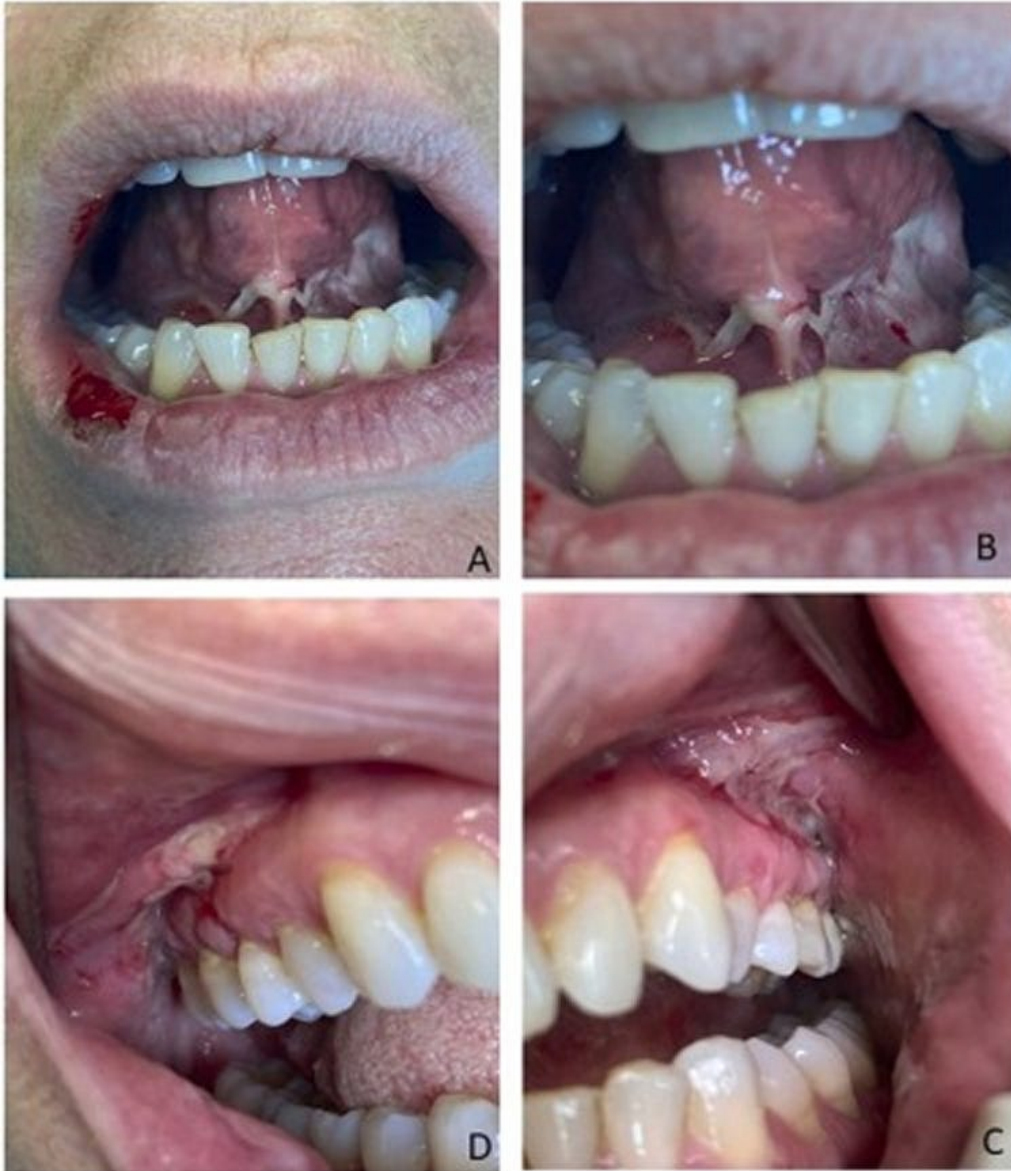[2022 Apr \(Desai et al\)](#) - Bullous Pemphigoid Following the Moderna mRNA-1273 Vaccine

- 73F had 2nd dose of Moderna mRNA
- 24 hours later she developed intensely itchy skin eruptions that started on the trunk and later spread to extremities and the face
- P/E: tense, filled bullae were noted throughout her trunk, extremities and face, ranging in size from 5 mm to 2 cm
- Diagnosis: bullous pemphigoid, treated with oral prednisone and mycophenolate mofetil



[2022 Apr \(Calabria et al\)](#) – Autoimmune mucocutaneous blistering diseases after SARS-Cov-2 vaccination: A Case report of Pemphigus Vulgaris and a literature review

- 60F had 2nd dose of Pfizer mRNA
- 7 days later presented with oropharyngeal and nasal bullous lesions
- Diagnosis: Pemphigus Vulgaris

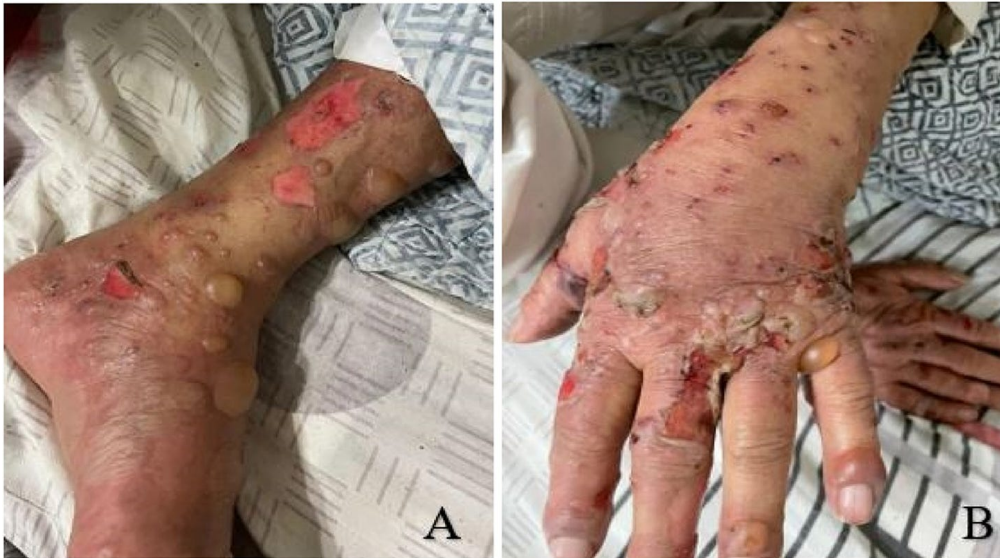

- Literature review of Autoimmune mucocutaneous blistering diseases after COVID-19 Vaccination (35 cases):
 - 23/35 (74%) – Bullous Pemphigoid
 - 6/35 (17%) – Pemphigus Vulgaris
 - 2/35 (6%) – Linear IgA Bullous Dermatitis
 - 1/35 (3%) – Pemphigus Foliaceus
 - 63% after Pfizer
 - 17% after Moderna
 - 9% after AstraZeneca
 - 9% after CoronaVac
 - All were treated with topical and or systemic corticosteroids

[2022 Mar \(Alshammari et al\)](#) – Bullous pemphigoid after second dose of mRNA- (Pfizer-

BioNTech) Covid-19 vaccine: A case report

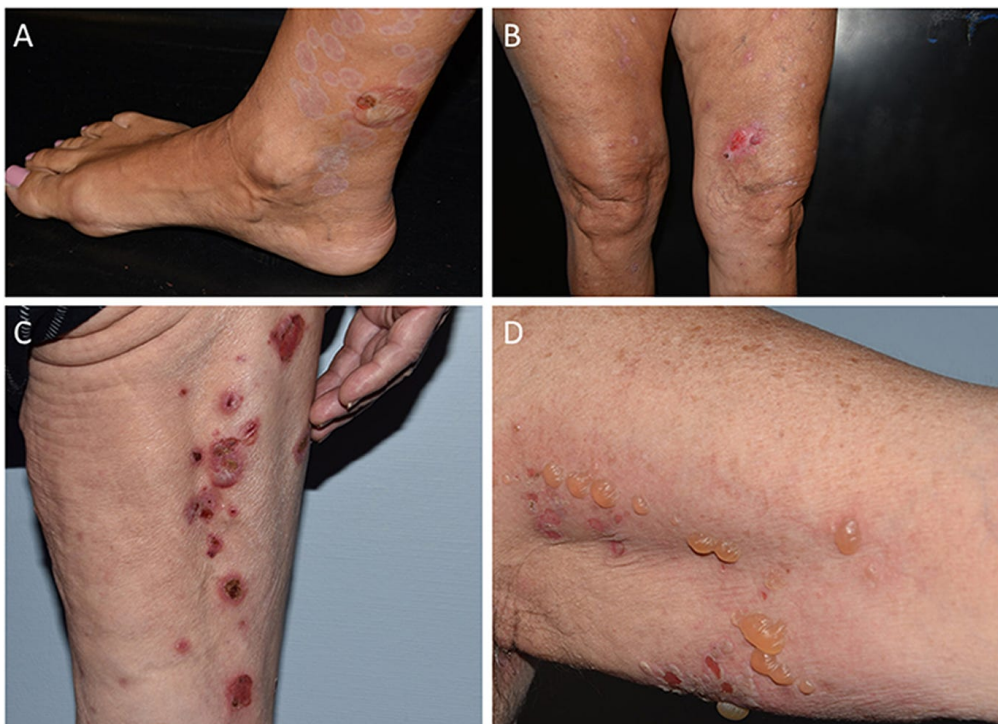- 78M had 2nd dose of Pfizer mRNA
- next day he developed an eruption of itchy skin lesions with bullae across his extremities
- Diagnosis: Bulloid Pemphigus, treated with oral steroids



[2022 Feb \(Maronese et al\)](#) – Bullous Pemphigoid Associated With COVID-19 Vaccines: An Italian Multicentre Study

- Bullous pemphigoid (BP) is an autoimmune bullous disease caused by circulating autoantibodies toward the hemidesmosomal antigens BP180 and BP230.
- Cases of BP have been described following vaccinations against tetanus, poliomyelitis, diphtheria, influenza, pneumococcus, meningococcus, hepatitis B and rabies.
- mechanism by which COVID-19-vaccines may induce BP has not been clarified.
- Literature review: 21 cases found
 - 17 had Pfizer, 2 Moderna, 1 AstraZeneca, 1 had AstraZeneca & Pfizer
 - median age 82 years
 - median latency between Vaccine dose and cutaneous lesions = 27 days
 - 11/17 had positive anti-BP180 auto-antibodies
 - 5/17 had positive anti-BP230 auto-antibodies

Examples in photographs below:



[Click here to read the full article.](#)

*

Note to readers: Please click the share button above. Follow us on Instagram and Twitter and subscribe to our Telegram Channel. Feel free to repost and share widely Global Research articles.

Dr. William Makis is a Canadian physician with expertise in Radiology, Oncology and Immunology. Governor General's Medal, University of Toronto Scholar. Author of 100+ peer-reviewed medical publications.

Featured image is from NaturalNews.com

The Worldwide Corona Crisis, Global Coup d'Etat Against Humanity

by Michel Chossudovsky


Michel Chossudovsky reviews in detail how this insidious project “destroys people’s lives”. He provides a comprehensive analysis of everything you need to know about the “pandemic” — from the medical dimensions to the economic and social repercussions, political underpinnings, and mental and psychological impacts.

“My objective as an author is to inform people worldwide and refute the official narrative which has been used as a justification to destabilize the economic and social fabric of entire countries, followed by the imposition of the “deadly” COVID-19 “vaccine”. This crisis affects humanity in its entirety: almost 8 billion people. We stand in solidarity with our fellow human beings and our children worldwide. Truth is a powerful instrument.”

Reviews

This is an in-depth resource of great interest if it is the wider perspective you are motivated to understand a little better, the author is very knowledgeable about geopolitics and this comes out in the way Covid is contextualized. —Dr. Mike Yeadon

In this war against humanity in which we find ourselves, in this singular, irregular and massive assault against liberty and the goodness of people, Chossudovsky’s book is a rock upon which to sustain our fight. —Dr. Emanuel Garcia



In this book, through science-based chapters, Michel traces the false covid pandemic, explaining how a PCR test, producing up to 97% proven false positives, combined with a relentless 24/7 fear campaign, was able to create a worldwide panic-laden “plandemic”; that this plandemic would never have been possible without the infamous DNA-modifying Polymerase Chain Reaction test – which to this day is being pushed on a majority of innocent people who have no clue. His conclusions are evidenced by renown scientists. —Peter Koenig

Professor Chossudovsky exposes the truth that “there is no causal relationship between the virus and economic variables.” In other words, it was not COVID-19 but, rather, the deliberate implementation of the illogical, scientifically baseless lockdowns that caused the shutdown of the global economy. —David Skripac

A reading of Chossudovsky’s book provides a comprehensive lesson in how there is a global coup d’état under way called “The Great Reset” that if not resisted and defeated by freedom

loving people everywhere will result in a dystopian future not yet imagined. Pass on this free gift from Professor Chossudovsky before it's too late. You will not find so much valuable information and analysis in one place. -Edward Curtin

ISBN: 978-0-9879389-3-0, Year: 2022, PDF Ebook, Pages: 164, 15 Chapters

Price: ~~\$11.50~~ FREE COPY! [Click here \(docsend\) and download.](#)

We encourage you to support the eBook project by making a donation through Global Research's [DonorBox "Worldwide Corona Crisis" Campaign Page](#).

The original source of this article is [COVID Intel](#)
Copyright © [Dr. William Makis](#), [COVID Intel](#), 2023

[Comment on Global Research Articles on our Facebook page](#)

[Become a Member of Global Research](#)

Articles by: [Dr. William Makis](#)

Disclaimer: The contents of this article are of sole responsibility of the author(s). The Centre for Research on Globalization will not be responsible for any inaccurate or incorrect statement in this article. The Centre of Research on Globalization grants permission to cross-post Global Research articles on community internet sites as long the source and copyright are acknowledged together with a hyperlink to the original Global Research article. For publication of Global Research articles in print or other forms including commercial internet sites, contact: publications@globalresearch.ca

www.globalresearch.ca contains copyrighted material the use of which has not always been specifically authorized by the copyright owner. We are making such material available to our readers under the provisions of "fair use" in an effort to advance a better understanding of political, economic and social issues. The material on this site is distributed without profit to those who have expressed a prior interest in receiving it for research and educational purposes. If you wish to use copyrighted material for purposes other than "fair use" you must request permission from the copyright owner.

For media inquiries: publications@globalresearch.ca