

Kidney Failure After Covid mRNA Vaccination. ANCA Positive Vasculitis

Medical Disaster Calls for Alert Doctors, Diagnostic Testing, and Intensive Treatment

By [Dr. Peter McCullough](#)

Theme: [Science and Medicine](#)

Global Research, March 21, 2023

[Courageous Discourse](#)

All Global Research articles can be read in 51 languages by activating the Translate Website button below the author's name.

To receive Global Research's Daily Newsletter (selected articles), [click here](#).

Follow us on [Instagram](#) and [Twitter](#) and subscribe to our [Telegram Channel](#). Feel free to repost and share widely Global Research articles.

Rapidly progressive kidney failure to the point of hemo- or peritoneal dialysis is a medical nightmare that must be avoided at all costs.

Patients with slowly advancing renal disease due to diabetes or other problems have months if not years to get ready for dialysis or plan for kidney transplantation.

Kidney failure requiring hospitalization or dialysis should never happen after a routine vaccine, yet it has occurred multiple times after COVID-19 mRNA injections (Pfizer or Moderna).

This side effect is not listed in any consent form, FAQ, or on the blank package insert for the EUA genetic products. I wonder how many patients have gone into renal failure, were hospitalized and or died after mRNA vaccination with no recognition that Pfizer or Moderna could have triggered the catastrophe?

Chen described nine cases of antineutrophil cytoplasmic antibody (ANCA) positive vasculitis that must be diagnosed with the ANCA test and often biopsy followed by intensive medical treatment. Doctors and nurses must act fast, otherwise the condition can be fatal. As you can see from the table 7 of 8 were spared dialysis but most had permanent kidney damage to deal with for the rest of their lives. Sadly, one patient went on dialysis.



Case Report: Anti-neutrophil Cytoplasmic Antibody-Associated Vasculitis With Acute Renal Failure and Pulmonary Hemorrhage May Occur After COVID-19 Vaccination

Chien-Chou Chen^{1,2}, Hsin-Yang Chen², Chun-Chi Lu³ and Shih-Hua Lin^{2*}

¹ Department of Internal Medicine, Tri-service General Hospital Songshan Branch, National Defense Medical Center, Taipei, Taiwan, ² Division of Nephrology, Department of Medicine, Tri-service General Hospital, National Defense Medical Center, Taipei, Taiwan, ³ Division of Rheumatology, Department of Medicine, Tri-service General Hospital, National Defense Medical Center, Taipei, Taiwan

TABLE 1 | ANCA with RPGN following COVID-19 vaccination.

No	Age/Sex	Past Hx	COVID-19 vaccination	Onset	Symptoms	Urinalysis	Blood test	ANCA type	Kidney Bx	Extra-renal involvement	Treatment	Outcome
1 st	52/M	HTN	Moderna	2 weeks after 2nd dose	Headache, Weakness	Dysmorphic RBC	SCr: 8.4 mg/dL	Anti-PR3 (+)	Pauci-immune necrotizing and crescentic GN	None	Homodilys: Rituximab CYC	Delayed-dependent
2 nd	81/M	Healthy	Moderna	Shortly after 2nd dose	Flu-like symptoms	NA	AKI	Anti-PR3 (+)	Pauci-immune crescentic GN with capillary necrosis & vasculitis	Pulmonary necrotic masses	Plasma exchange, Pulse steroid CYC	Improved renal function
3 rd	77/M	Healthy	AstraZeneca	4 weeks after 1st dose	Fever, Night sweating, Anorexia	NA	SCr: 2.7 mg/dL, CRP: 20 mg/dL	NA	Non-crescentic, non-necrotizing granuloma	None	Pulse steroid	Resolved renal function
4 th	78/F	DM, HTN	Pfizer-BioNTech	Immediate after 2nd dose	Nausea, vomiting, diarrhea, lethargy	Dysmorphic RBC, UA CR: 2,050 mg/g	SCr: 3.5 mg/dL	Anti-MPO (+)	Necrotizing crescentic GN	None	Rituximab	Improved renal function (SCr: 1.7 mg/dL)
5 th	29/F	Congenital cystic lung disease	Pfizer-BioNTech	7 weeks after 2nd dose	NA	Hematuria, UA CR: 633 mg/g	SCr: 1.9 mg/dL	Anti-MPO (71 AU/mL)	Pauci-immune crescentic GN	Chronic lung infiltration	Pulse steroid, Rituximab CYC	Improved renal function (SCr: 1.0 mg/dL)
6 th	63/M	Healthy	AstraZeneca	1 week after 1st dose	Hemoptysis, Flu-like symptoms	Microscopic hematuria	SCr: 2.9 mg/dL	Anti-MPO (12 IU/mL)	Focal class of pauci-immune crescentic GN	Infiltration over LLL	Pulse steroid	Improved renal function (SCr: 2.1 mg/dL)
7 th	79/F	HTN	Pfizer-BioNTech	2 weeks after 2nd dose	Weakness, Upper thigh pain	Hematuria, UA CR: >18,000 mg/g, Eosinophils: 23.3%	SCr: 6.57 mg/dL	Anti-MPO (>134 IU/mL)	Vasculitis with pauci-immune crescentic GN	OK: 14,243 U/L Myoglobinemia >12,000 µg/L	Pulse steroid CYC	Resolved renal function
8	70/F	UTI	Moderna	9 weeks after 1st dose	Headache, Hemoptysis	Dysmorphic RBC, UA CR: 4,384 mg/g	SCr: 3.5 mg/dL, CRP: 2.7 mg/dL	Anti-MPO (378 IU/mL)	Vasculitis with pauci-immune crescentic GN	Pulmonary vasculitis	Plasma exchange, Pulse steroid, Rituximab	Improved renal function (SCr: 2.5 mg/dL)

CYC, Cyclophosphamide; Hx, history; Bx, biopsy; NA, Not applicable; PR3, proteinase 3; ANCA, anti-neutrophil cytoplasmic antibody; HTN, hypertension; DM, diabetes mellitus; SCr, serum creatinine; GN, glomerulonephritis; UA CR, urine protein creatinine ratio; CRP, C-Reactive protein; LLL, left lower lung.

Chen CC, Chen HY, Lu CC, Lin SH. Case Report: Anti-neutrophil Cytoplasmic Antibody-Associated Vasculitis With Acute Renal Failure and Pulmonary Hemorrhage May Occur After COVID-19 Vaccination. *Front Med (Lausanne)*. 2021 Nov 11;8:765447. doi: 10.3389/fmed.2021.765447. PMID: 34859017; PMCID: PMC8632021.

This paper serves as a reminder for doctors who are evaluating patients with constitutional symptoms weeks to months after mRNA vaccination to have a low threshold for routine common testing including serum creatinine and urinalysis. When early renal failure is detected additional testing including ANCA must be drawn and care should be elevated to specialists familiar with ANCA positive syndromes.

If you find “Courageous Discourse” enjoyable and useful to your endeavors, please subscribe as a paying or founder member to support our efforts in helping you engage in these discussions with family, friends, and your extended circles.

*

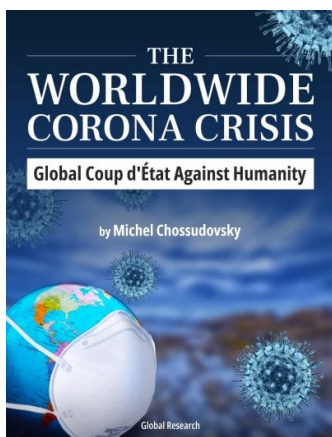
Note to readers: Please click the share buttons above. Follow us on Instagram and Twitter and subscribe to our Telegram Channel. Feel free to repost and share widely Global Research articles.

Source

[Chen CC, Chen HY, Lu CC, Lin SH. Case Report: Anti-neutrophil Cytoplasmic Antibody-Associated Vasculitis With Acute Renal Failure and Pulmonary Hemorrhage May Occur After](#)

[COVID-19 Vaccination. Front Med \(Lausanne\). 2021 Nov 11;8:765447. doi: 10.3389/fmed.2021.765447. PMID: 34859017; PMCID: PMC8632021.](#)

Featured image is from [FiercePharma](#)



The Worldwide Corona Crisis, Global Coup d'Etat Against Humanity

by Michel Chossudovsky

Michel Chossudovsky reviews in detail how this insidious project “destroys people’s lives”. He provides a comprehensive analysis of everything you need to know about the “pandemic” — from the medical dimensions to the economic and social repercussions, political underpinnings, and mental and psychological impacts.

“My objective as an author is to inform people worldwide and refute the official narrative which has been used as a justification to destabilize the economic and social fabric of entire countries, followed by the imposition of the “deadly” COVID-19 “vaccine”. This crisis affects humanity in its entirety: almost 8 billion people. We stand in solidarity with our fellow human beings and our children worldwide. Truth is a powerful instrument.”

[Conservative Risk Benefit Analyses Decide Against COVID-19 Vaccination](#)

ISBN: 978-0-9879389-3-0, Year: 2022, PDF Ebook, Pages: 164, 15 Chapters

Price: ~~\$11.50~~ Get yours for FREE! [Click here to download.](#)

We encourage you to support the eBook project by making a donation through Global Research’s [DonorBox “Worldwide Corona Crisis” Campaign Page](#).

The original source of this article is [Courageous Discourse](#)
Copyright © [Dr. Peter McCullough](#), [Courageous Discourse](#), 2023

[Comment on Global Research Articles on our Facebook page](#)

[Become a Member of Global Research](#)

Articles by: [Dr. Peter McCullough](#)

Disclaimer: The contents of this article are of sole responsibility of the author(s). The Centre for Research on Globalization will not be responsible for any inaccurate or incorrect statement in this article. The Centre of Research on Globalization grants permission to cross-post Global Research articles on community internet sites as long the source and copyright are acknowledged together with a hyperlink to the original Global Research article. For publication of Global Research articles in print or other forms including commercial internet sites, contact: publications@globalresearch.ca

www.globalresearch.ca contains copyrighted material the use of which has not always been specifically authorized by the copyright owner. We are making such material available to our readers under the provisions of "fair use" in an effort to advance a better understanding of political, economic and social issues. The material on this site is distributed without profit to those who have expressed a prior interest in receiving it for research and educational purposes. If you wish to use copyrighted material for purposes other than "fair use" you must request permission from the copyright owner.

For media inquiries: publications@globalresearch.ca